Classification of the Medical Important Protozoa

Phylum Sarcomastigophora 變形鞭毛蟲門
Subphylum Mastigophora 鞭毛蟲亞門
Class Zoomastigophorea 動鞭毛蟲綱

Flagellates
鞭毛蟲

Subphylum Sarcodina 變形蟲亞門
Superclass Rhizopoda 根足蟲超綱
Class Lobosea 變形蟲綱

Amoeba
亞米巴原蟲

Phylum Apicomplexa 頂端複合門
Class Sporozoea 孢子蟲綱
Subclass Coccidia 球蟲亞綱
Subclass Piroplasmia 梨漿片亞綱

Sporozoa
孢子蟲

Phylum Cilophora 纖毛蟲門
Class Kinetofragminophorea 動基裂綱
Subclass Vestibuliferia

Ciliates
纖毛蟲

Balantidium coli 大腸纖毛蟲

The only ciliate which can parasitize humans,
causing **balantidiasis**

Malmsten was the first to recognize the organism in two humans with dysentery in the year 1857.

A ciliate normally parasitic in



World-wide distribution
More commonly found
amongest those who keep pigs,
especially in warmer climates

Areas of high prevalence include regions of Latin America, the Philippines, Papua New Guinea and West Iran, and areas of the Middle East

Morphology of *Balantidium coli*

Ciliates

Large oval shaped,
30~300 x 40~70 um
Body covered with cilia
Foamy cytoplasm
Marco- and micronucleus can be seen

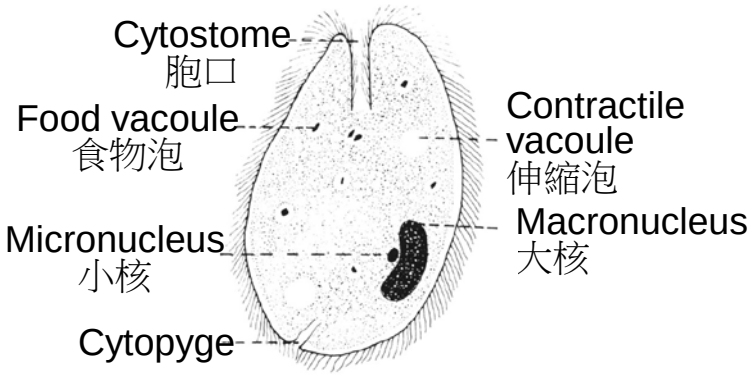

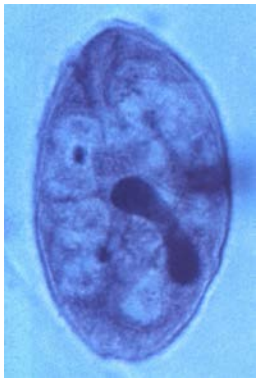

Cyst

Large spherical,
40~60 um
Thick cyst wall composed of 2 layers
Macronucleus visible

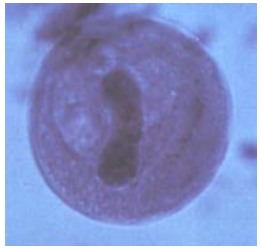

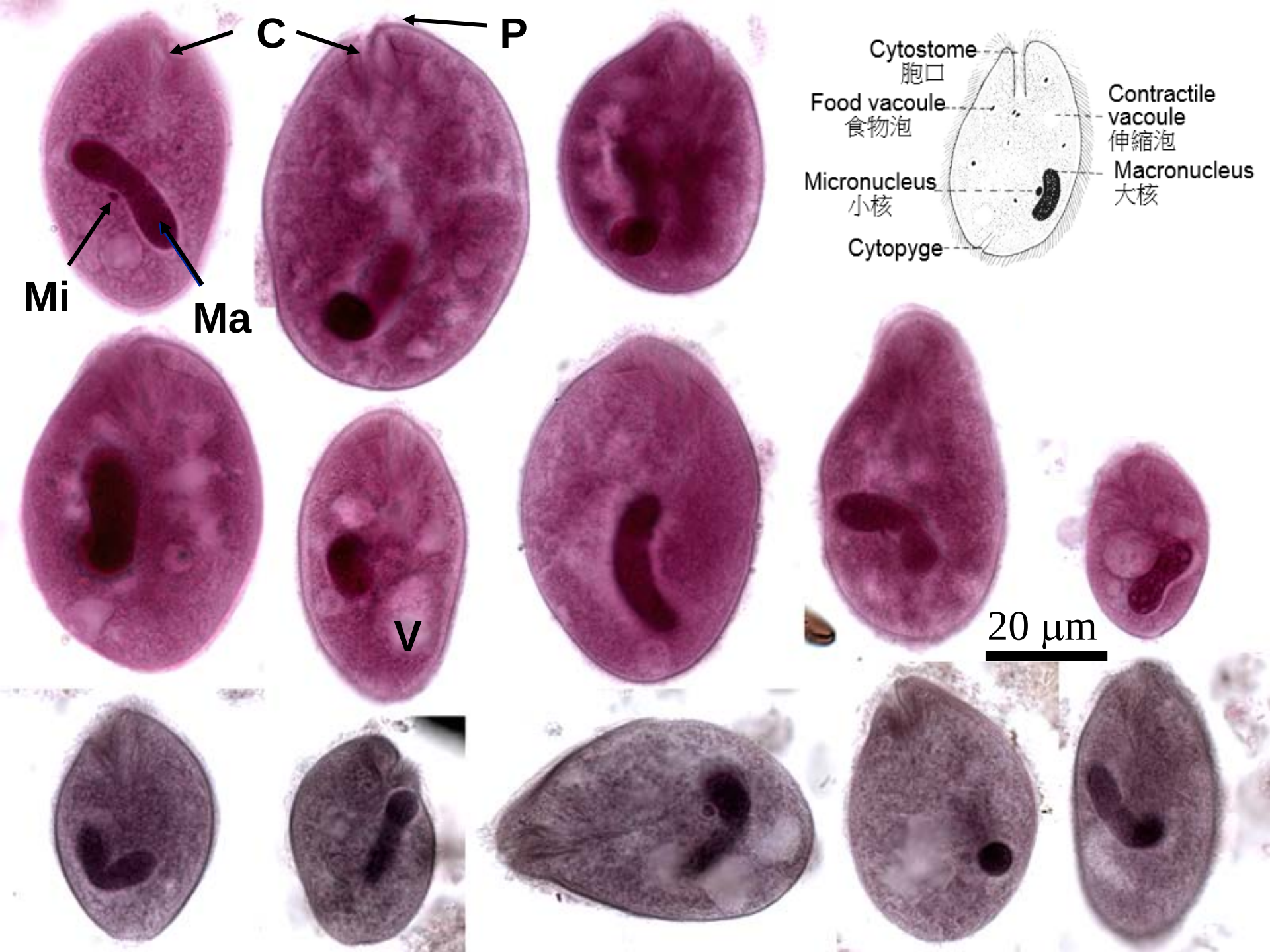
C
P
Mi
Ma
V
Cytostome
胞口
Food vacoule
食物泡
Contractile
vacoule
伸縮泡
Micronucleus
小核
Macronucleus
大核
Cytopyge
20 μm

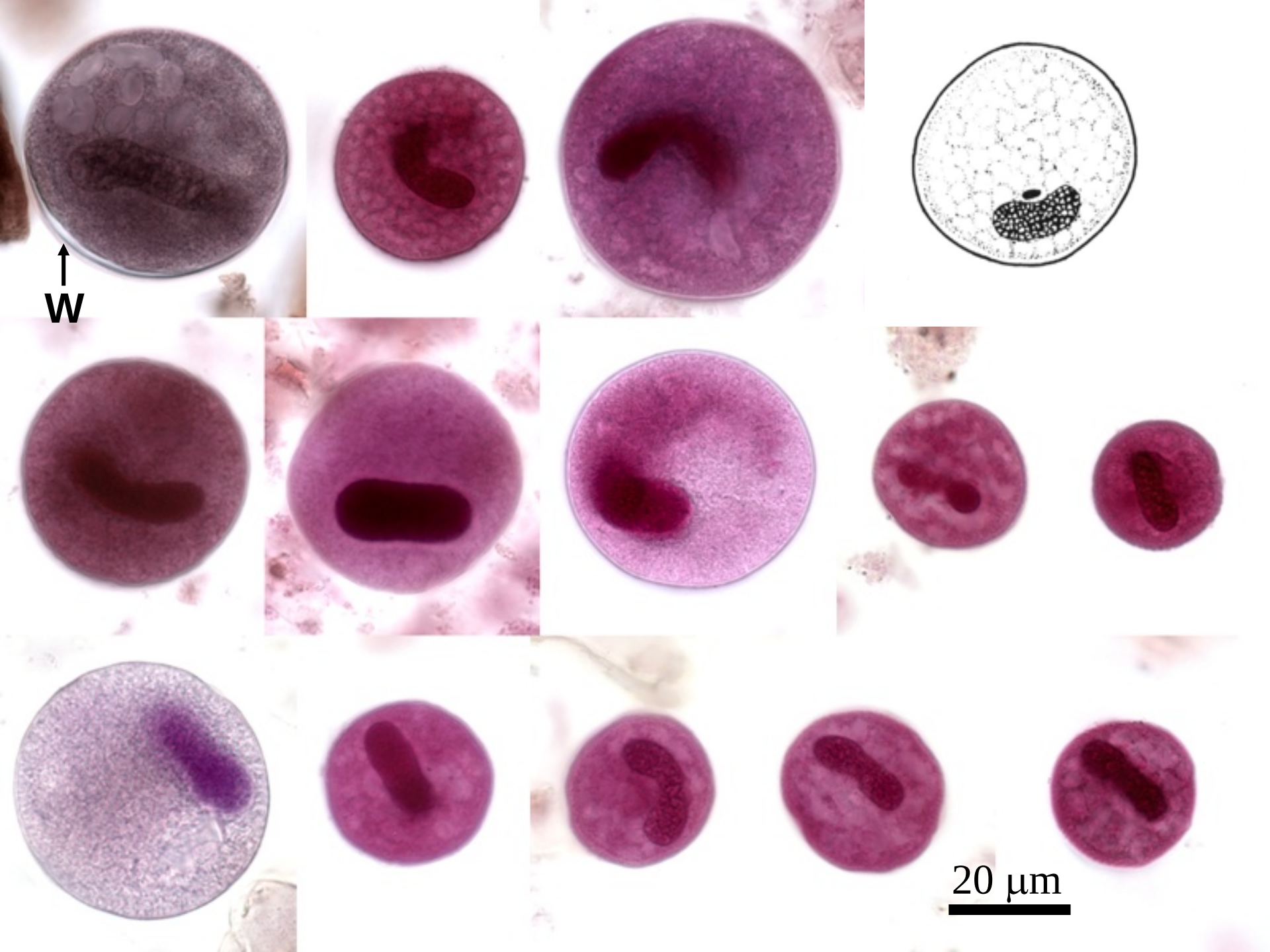
W
20 µm

Life Cycle of *Balantidium coli*

EXTERNAL ENVIRONMENT

Infective cyst
感染性囊體

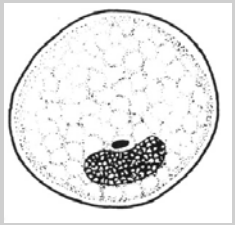

Cyst ingested



Excyst 脫囊 in small intestine

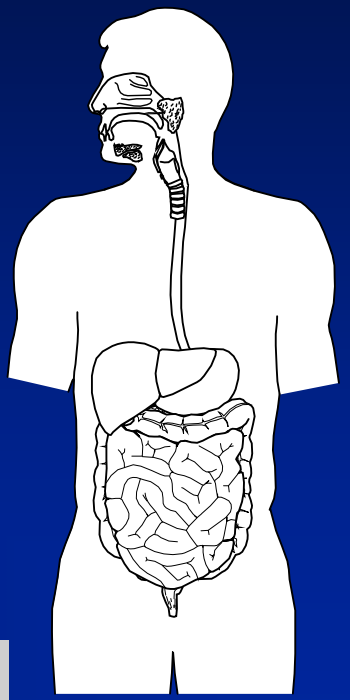

Multiply in colon

Conjugation 接合生殖
Binary fission 二分法分裂

Encyst

Cyst in faeces

Clinical Features

Usually symptomless or
characterized by intermittent diarrhea and constipation

- When invade intestinal wall cause inflammation and
  flask-shaped ulcers (三角錐瓶狀潰瘍)
  Dysentery with blood and mucus

- Serious complications are rare
  Intestinal perforation

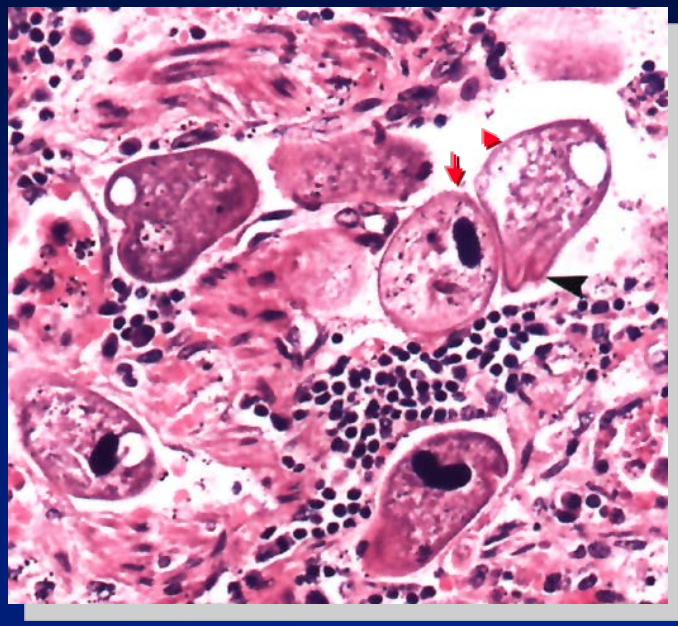

In a survey of 325 waterborne diseases in North America and Europe, Balantidium infections accounted for 0.3% (n=1) of the outbreaks.

A comprehensive study of stool samples from 2,000 Aymara Indian children from the Altiplano region of Bolivia found widespread infection with balantidia but a low level of fulminant disease among the children. The overall prevalence of B. coli was 1.2% (range, 1.0 to 5.3%). More than half of the pigs (n=50) in the same communities were infected with balantidia, as determined by examination of stool samples.

Pathology of Balantidiasis

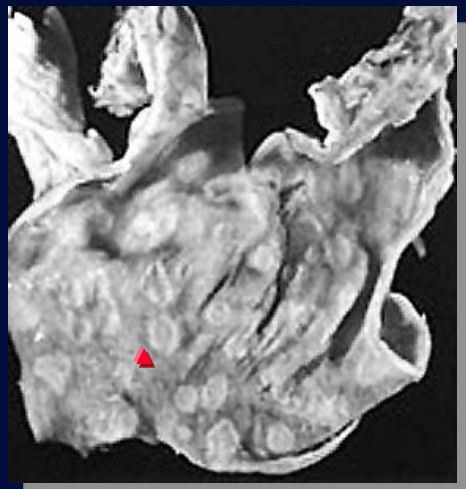

Balantidiasis colon ulcers

Colon with ulceration and necrosis



Flask-shaped ulcers

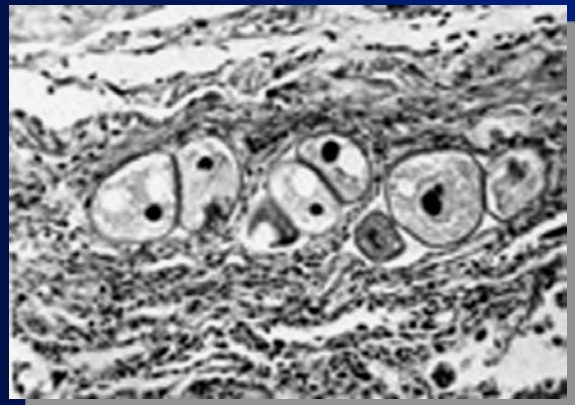

Trophozoites at the base of colonic ulcer

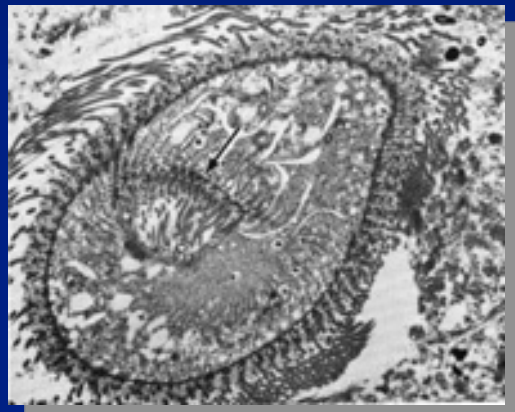

EM of trophozoite in clon

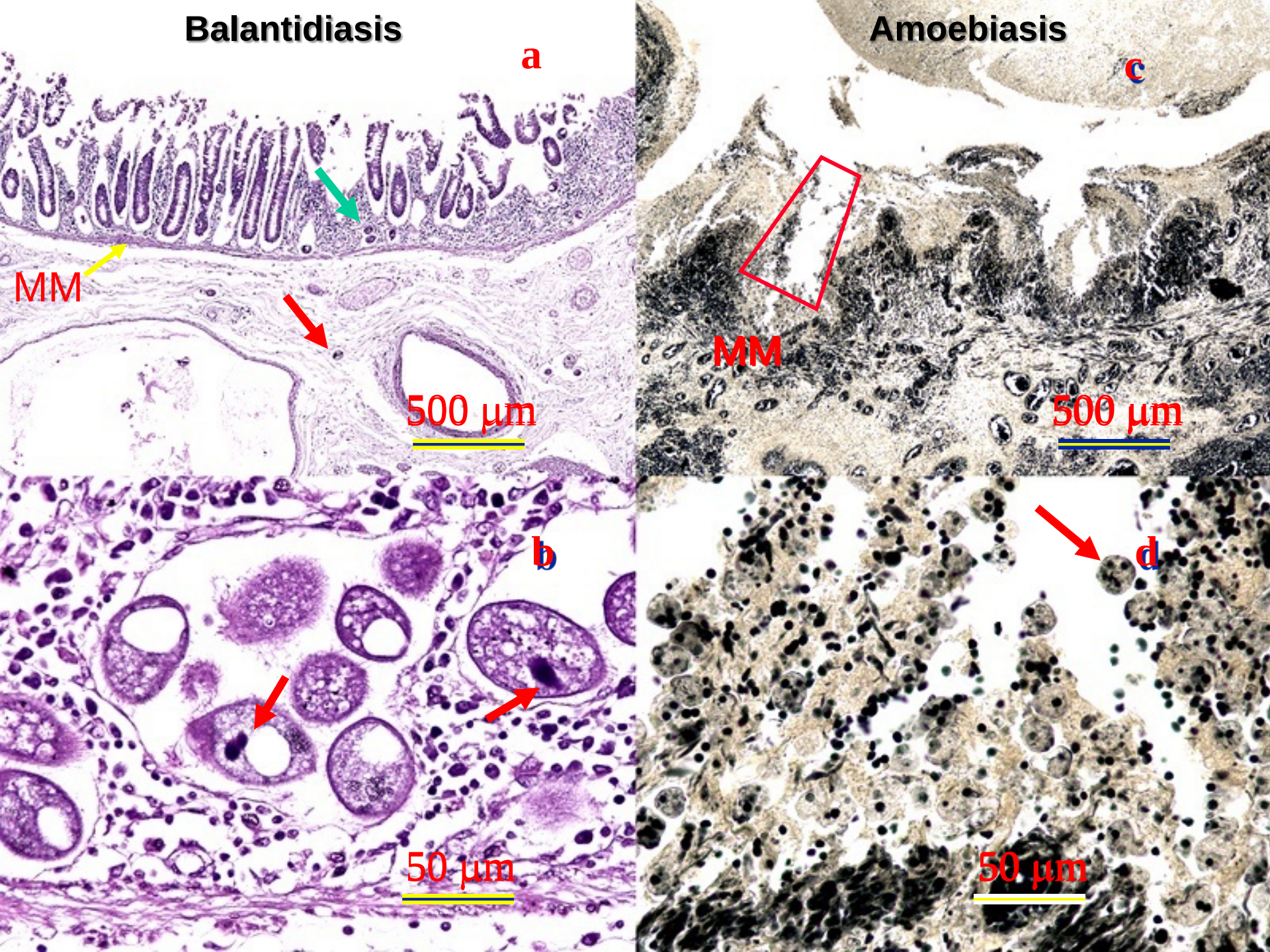
Balantidiasis
a
MM
500 µm
b
50 µm
Amoebiasis
c
MM
500 µm
d
50 µm

Laboratory Diagnosis

Mix small amount of faeces in saline with Dobell's iodine

- **Finding ciliates in dysenteric faecal specimens**

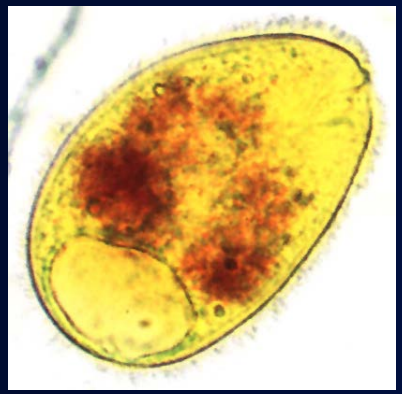

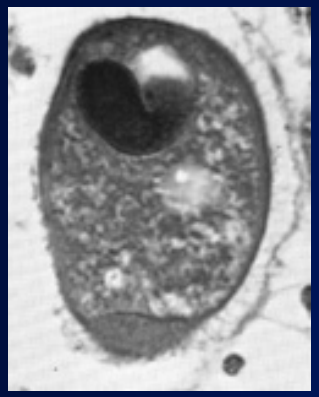

Large oval shaped,
30~300 x 40~70 um
Rapid revolving motility
Cilia can be seen
Marco- and micronucleus
**B. coli* ciliates degenerate rapidly in feces

- **Finding cyst in formed or semiformed faeces**

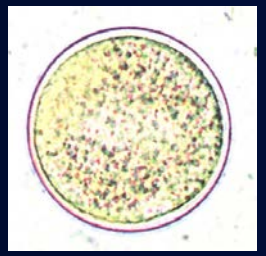

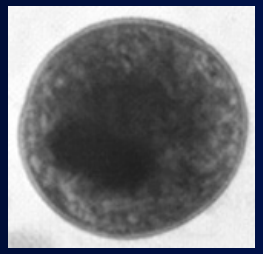

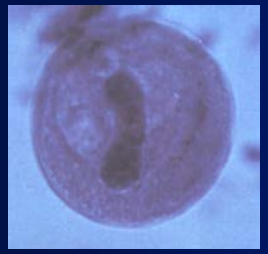

Large spherical,
40~60 um
Thick walled
Macronucleus visible

Metronidazole (Flagyl) a disulfiram drug

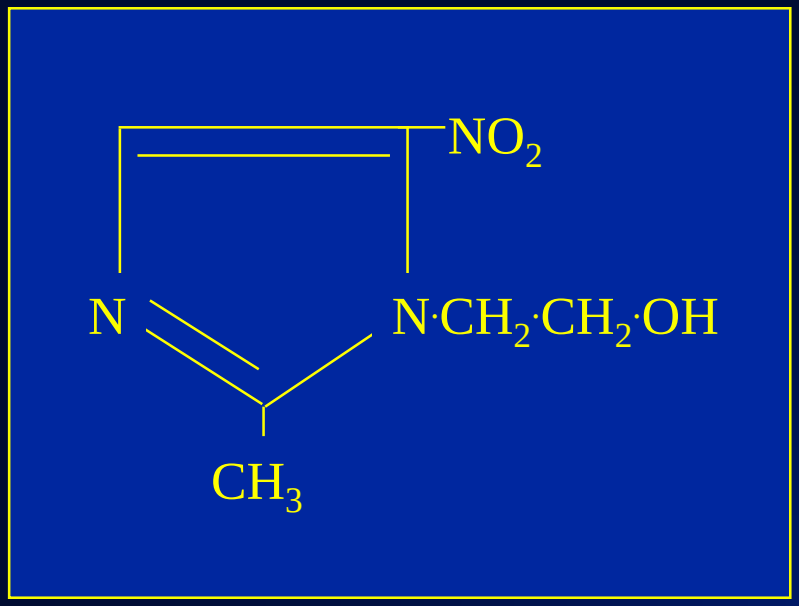

Side effects
nausea
dryness of the mouth
perception of metallic taste
consequent anorexia
intolerance to alcohol
tetratogenic in animals

Dosage:
2.0 g per day for 7 days; 250 mg, tid for 5 days
<2 yrs - 125 mg/day; 2~4 yrs: 250 mg/day;
4~8 yrs: 375 mg/day; 8~2 yrs: 500 mg/day

Potential carcinogenic and mutagenic in rodents
Not to be used by women
during the first three months of pregnancy and
newborns during the first six weeks of life

FLAGELLATES 鞭毛蟲

Lumen-Dwelling Flagellates 腔道鞭毛蟲

- **Intestinal** 腸道
- **Uro-genital** 泌尿生殖道
- **Oral** 口腔

Blood & Tissue Flagellates 血液及組織鞭毛蟲

Lumen-Dwelling Flagellates 腔道鞭毛蟲

Pathogenic (致病) Opportunistic (伺機性) Commensal (共生)

Intestinal 腸道

- ***Giardia Lamblia*** 梨形鞭毛蟲
  Chilomastix mesnili 唇形鞭毛蟲
  Pentatrichomonas hominis 人腸道鞭毛蟲
  Retortamonas intestinalis 腸滴蟲(腸旋滴蟲)
  Enteromonas hominis 恩特若姆那斯鞭毛蟲
  Dientamoeba fragilis 雙核阿米巴

Uro-Genital 泌尿生殖道

- ***Trichomonas vaginalis*** 陰道鞭毛蟲

Oral 口腔

Trichomonas tenax 口腔鞭毛蟲

Giardia lamblia 梨形鞭毛蟲

Vilem Lambl

Two hundred years after van Leeuwenhoek had seen Giardia parasites, in 1859, a Czech physician named Vilem Lambl observed *Giardia intestinalis* in the stools of children with diarrhea, but believed the protazoa to be commensal and not responsible for the pathology. The species was then named *Giardia lamblia* in his name. The question as to whether giardia was a pathogen or commensal was debated for many decades during the first part of the twentieth century.

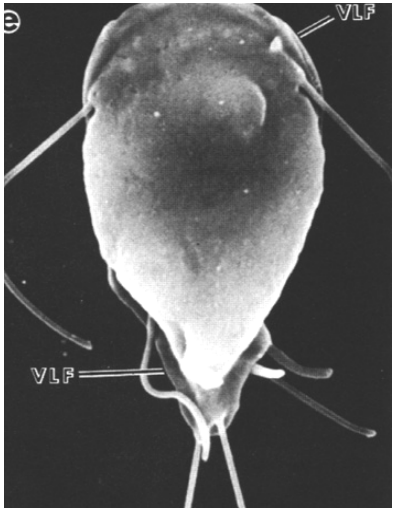

Giardiasis (Traveller's disease) is particularly common in the tropics and subtropics.
In areas where where water suppplies and the enivrnoment become faecally contaminated.

Transmission

Faecal-oral route : by the ingestion of cysts in food or water contaminated with faeces containing cysts.

***G. lamblia* cyst (囊體)**
卵圓形
長約 8~14 um, 寬約 5~10 um
囊壁呈雙層
含有 2 或 4 個核及
2 個軸柱 (axostyle)

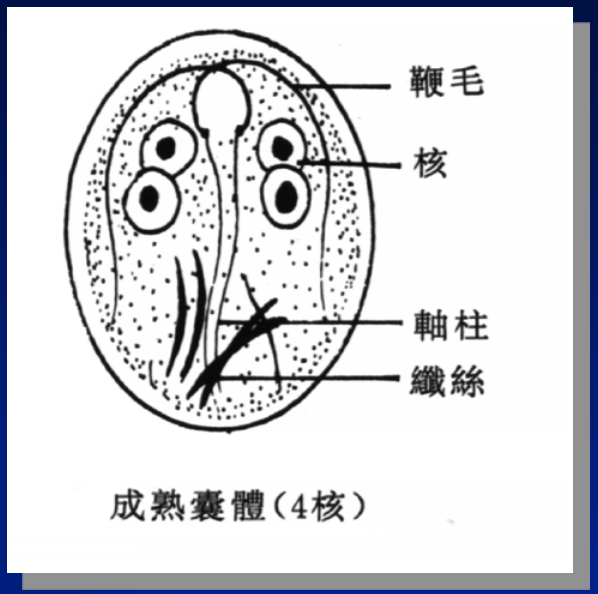

Remain infective for 1 month at 21°C
Not killed in food or water stored at 4°C.
Resistant to chlorine

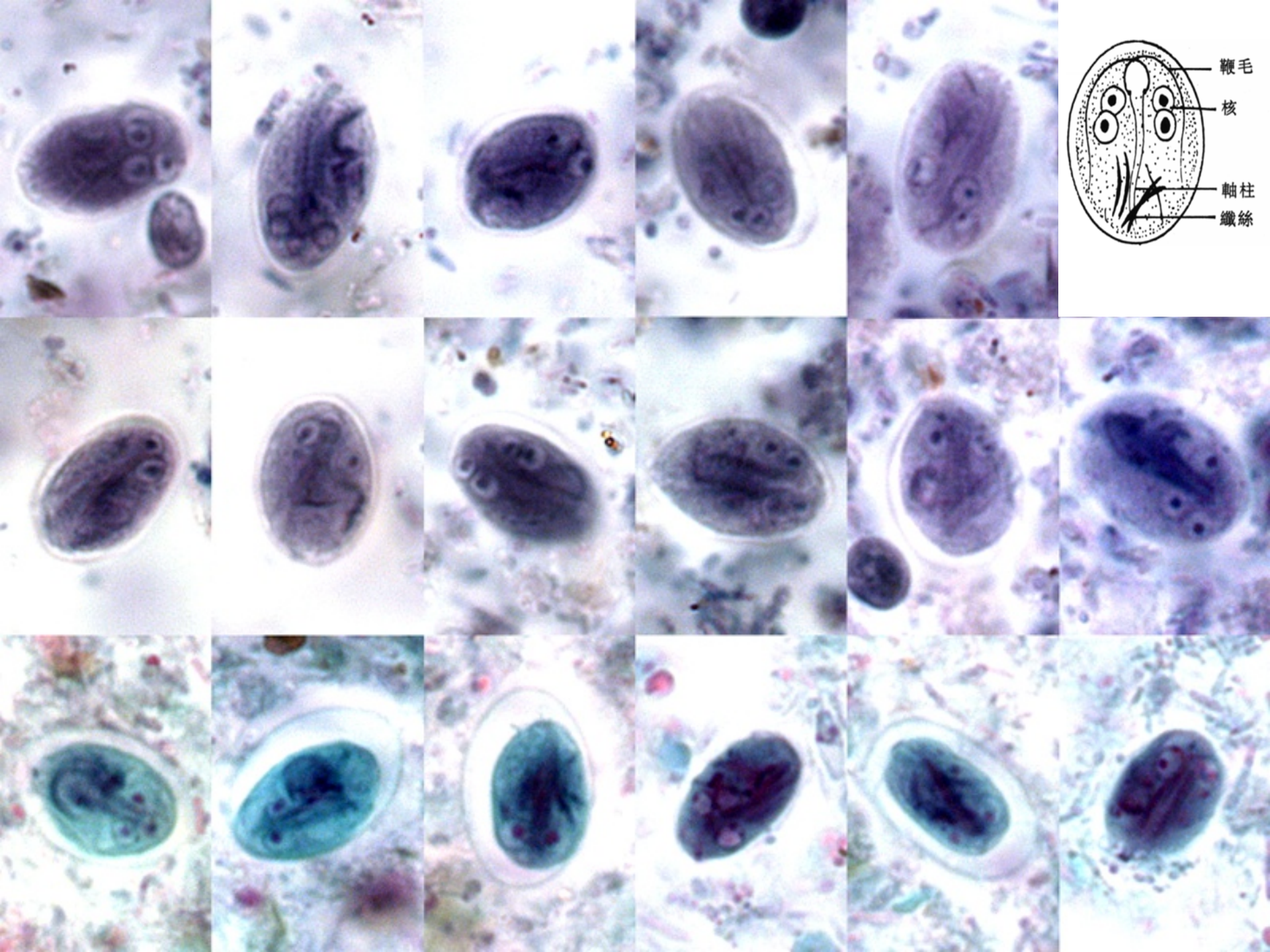
鞭毛
核
軸柱
纖絲

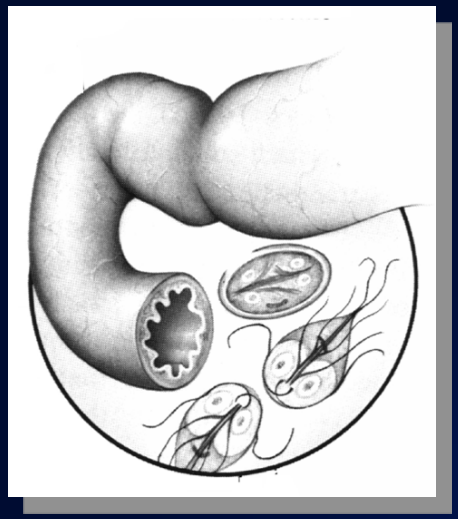

cyst → trophozoite

Cyst excyst 脫囊
in the upper small intestine 十二指腸
to form trophozoites 營養體

G. lamblia trophozoite

扁平呈梨形,
長寬約 10~15 x 6~9 um, 厚約 3 um
兩側對稱, 前端較寬, 腹面凹陷
左右兩側各具有一個吸盤 (sucking disk)
蟲體具 8 根鞭毛
(4 側, 2 腹, 2 尾)
2 個大型細胞核,

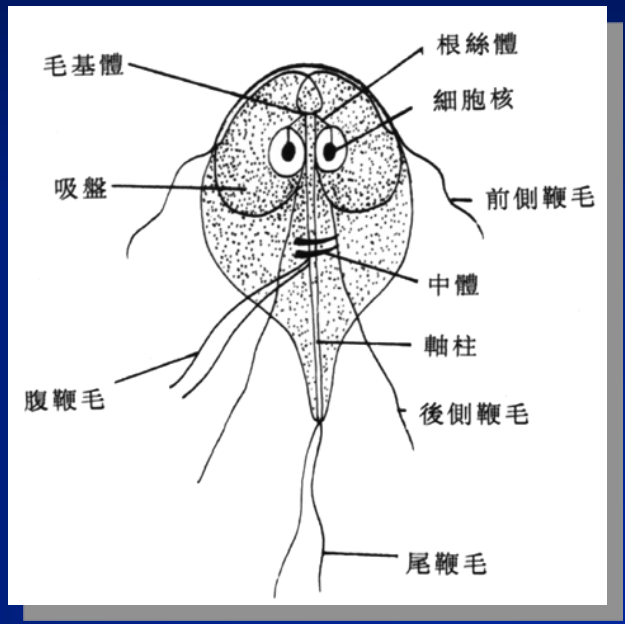

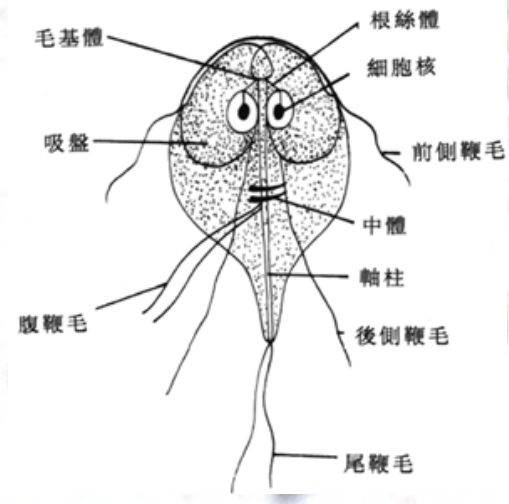
毛基體
根絲體
細胞核
吸盤
前側鞭毛
中體
軸柱
腹鞭毛
後側鞭毛
尾鞭毛

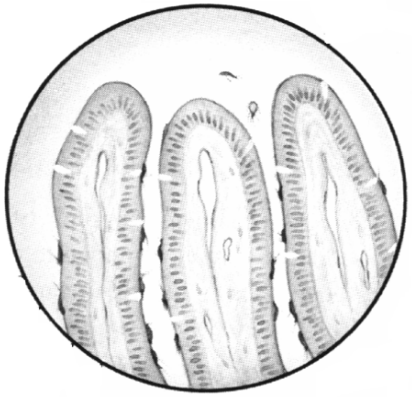

Trophozoits live on surface of villi 絨毛

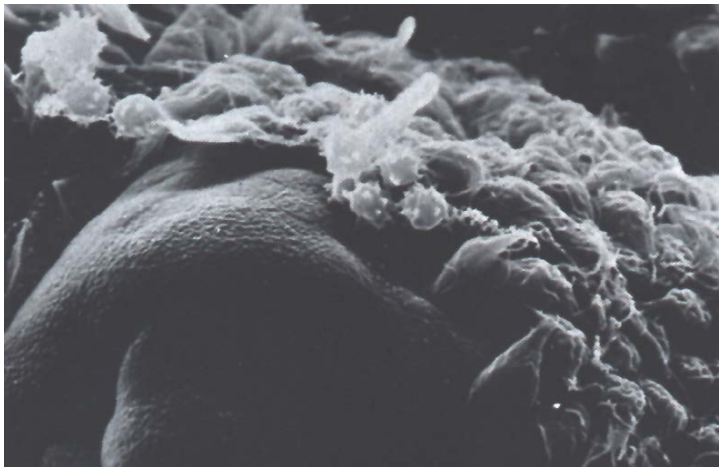

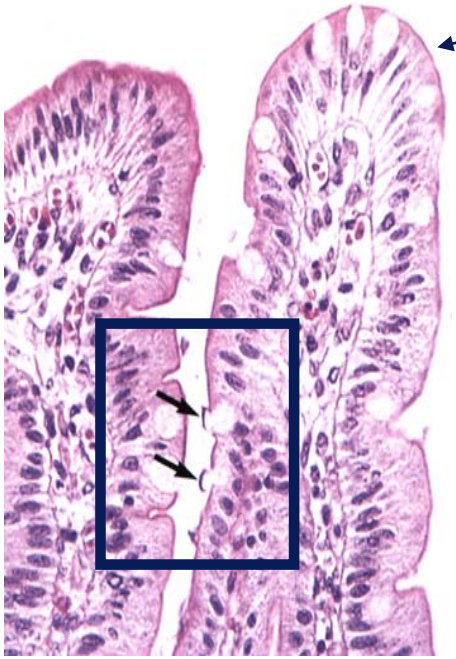

villi of upper smal intestine

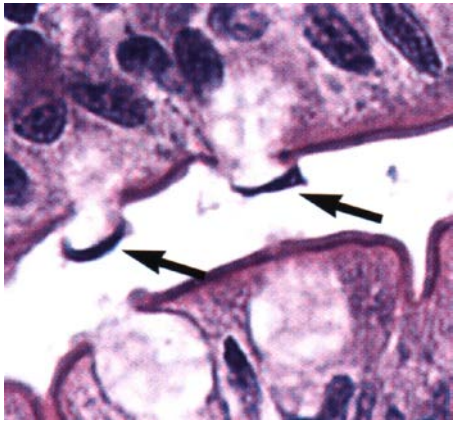

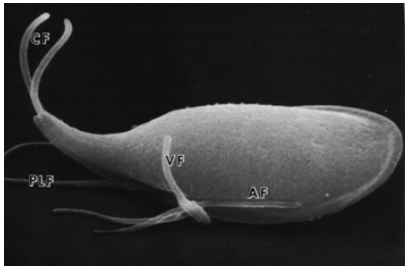

G. lamblia trophozoite

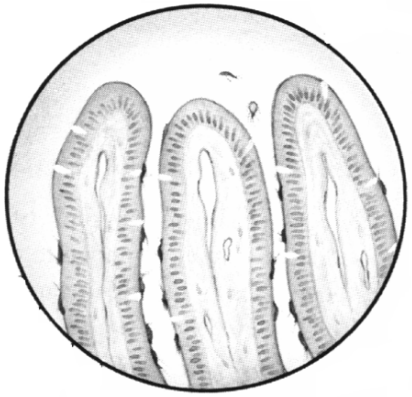

Trophozoites attached to duodenal villi 絨毛

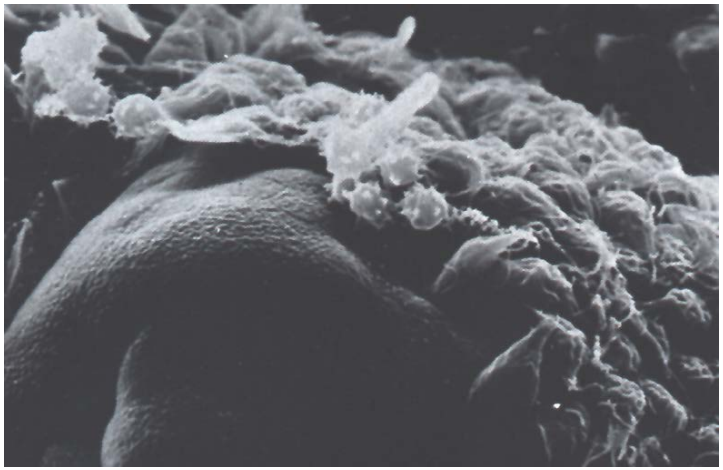



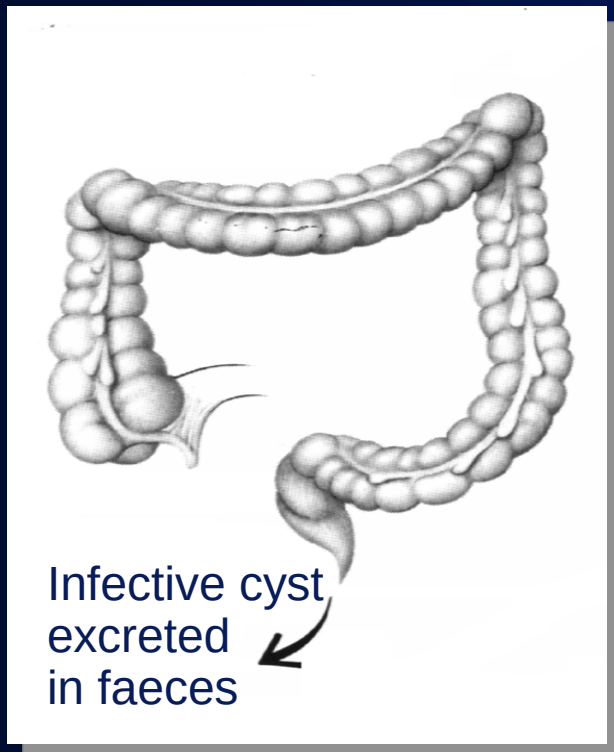

Infective cyst excreted in faeces



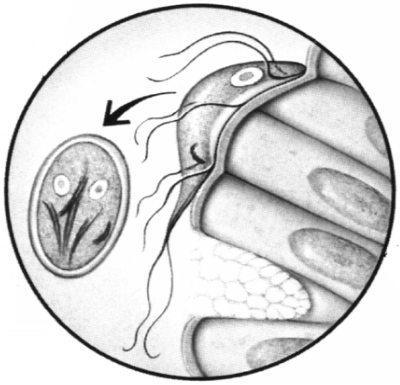

Trophozoites detached and encyst
形成囊體

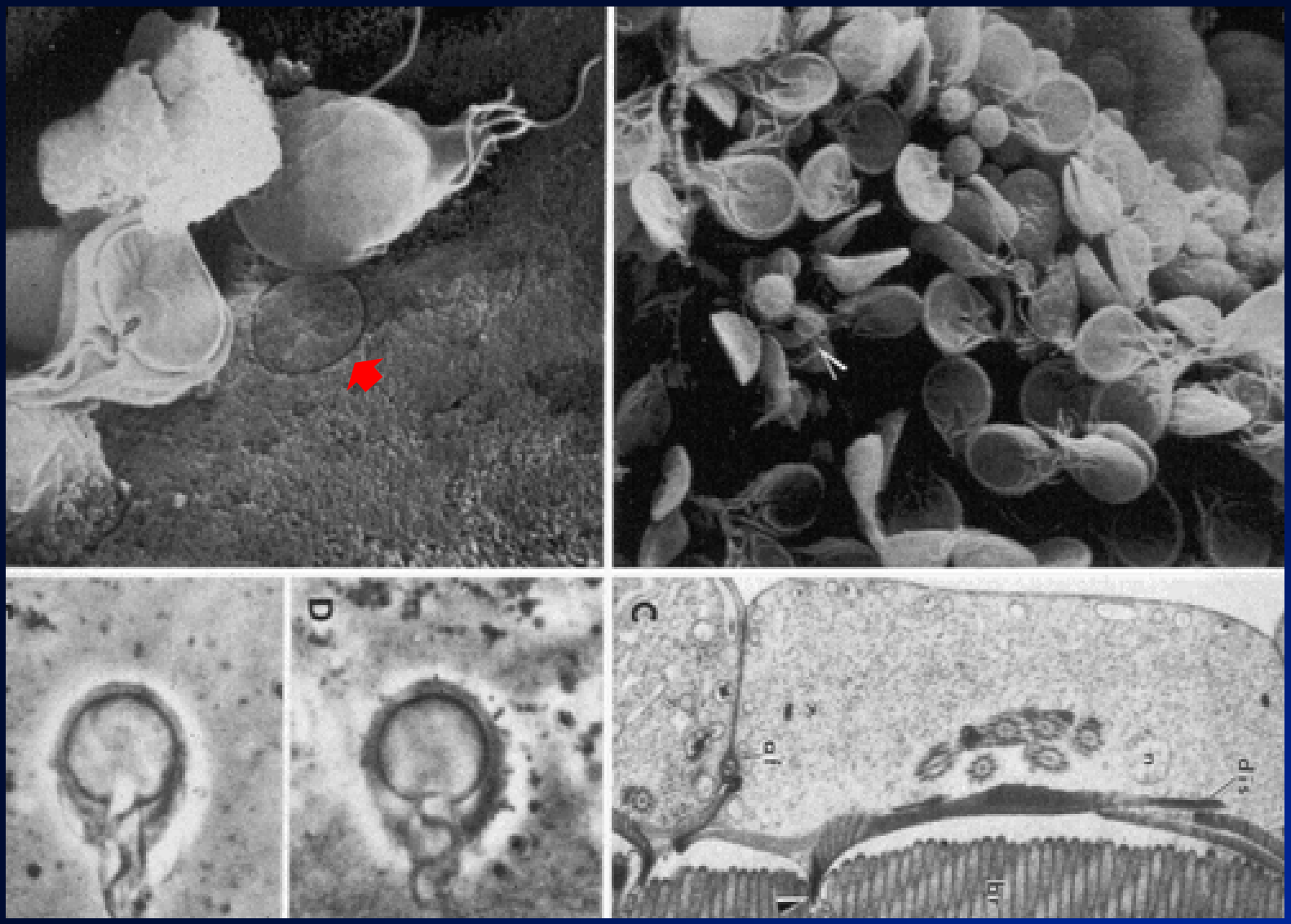

Note the impression left on the epithelia where a trophozoite has detached (upper left) and the interaction between the ventral disk of the parasite and the brush boarder cells of the intestines (lower right).

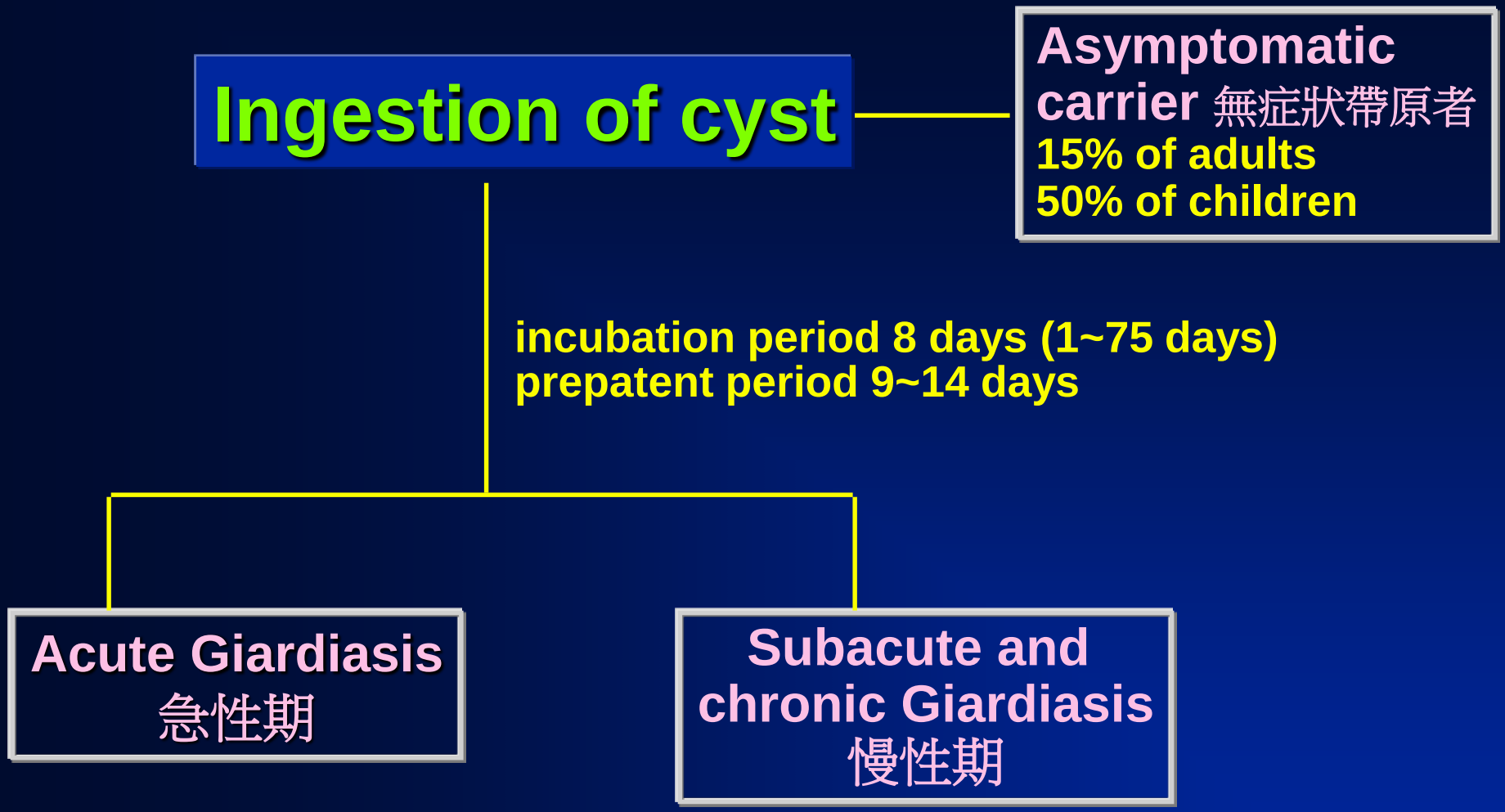
Ingestion of cyst
Asymptomatic carrier 無症狀帶原者
15% of adults
50% of children
incubation period 8 days (1~75 days)
prepatent period 9~14 days
Acute Giardiasis
急性期
Subacute and chronic Giardiasis
慢性期

Acute Giardiasis

First Signs
nausea, anorexia, malaise,
uneasiness in the upper intestine.
low grade fever and chills

Onset
acute,
explosive, watery, offensive diarrhea.
stool frequency 3~8 times a day
no blood, pus or mucus in stools
flatulence
marked abdominal distension
vomitimg foul sulfuric belching
upper to midepigastric cramps
lasts for 3 to 4 days

→ **Infection clear sponatneously**

→ **Change to asymptomatic form**

→ **Continue for months in acute form**

→ **Subacute and chronic Giardiasis**

Acute viral enteritis, *Campybacter* infection
Bacillary dysentery, Food poisoning
Acute intestinal amebiasis, Toxic *E. coli*

Subacute and Chronic Giardiasis

periodic, brief episodes of loose foul stools
bulky, yellowish, and forthy
intestinal gurgling
increased abdominal distension
alternative steatorrhea(脂肪便) & constipation(便秘)
anorexia, nausea
epigastric uneasiness
Malabsorption of lactose(乳糖), xylose(木糖), vitamin A, B_{12} and fats

Infection persist for years

urticaria (蕁麻疹)
lassitude (疲勞)
headaches (頭疼)
myalgias (肌痛)

Infection clear Spontaneously (自動痊愈)

梨形鞭毛蟲症引起之吸收不良及組織切片特徵

	嚴重感染	輕度感染
小腸功能	吸收不良 脂肪 **D-xylose (木醛糖)** 維他命 **A, B_{12}** 乳糖無耐受力	吸收正常或 只有 **D-xylose**吸收不良 乳糖無耐受力 **(Lactose intolerance)**
組織切片形態	小腸絨毛變厚, 變短, 或萎縮 隱窩 **(crypt)** 變深 細胞侵潤增加 絨毛間可發現活動體	組織切片正常

Jejunal Biopsy from Patients with Giardiasis

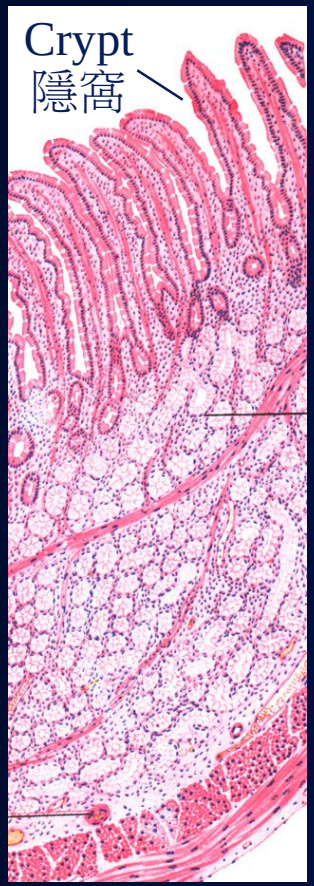

Normal villi

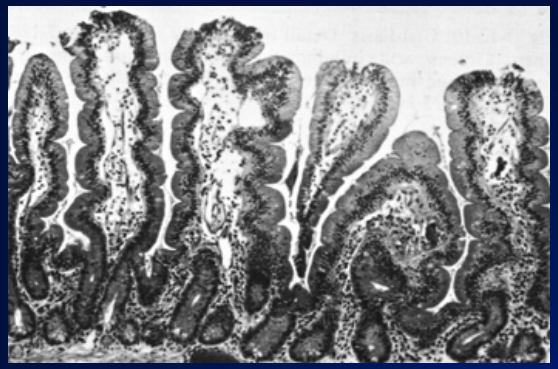

No significant symptoms

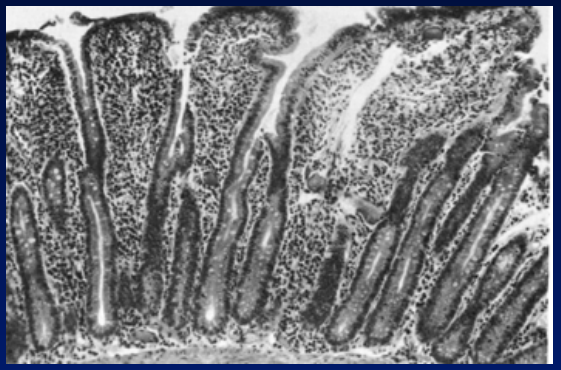

Severe diarrhoea, weight loss and mlabsorption

Diarrhoea for 1 mth

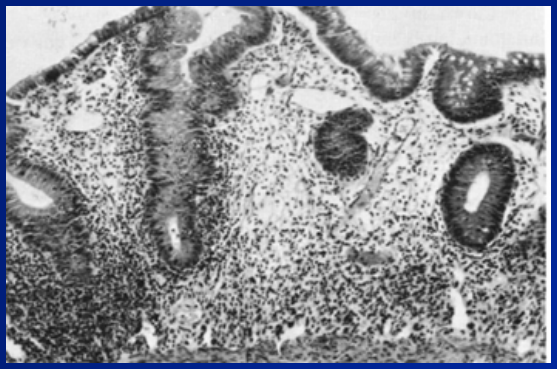

Long standing diarrhoea

Laboratory Diagnosis

- Stool examination
  - finding cyst in faeces
  - finding motile flagellates in diarrhoeic faeces
- Enterotest capsule (string) Test for recovery of flagellates
- Finding flagellates in duodenal aspirates
- Small bowel biopsy
- Immunodiagnosis

Enterocapsule (String) Test

HEDECO Comapny, Mountain View, CA 94043, USA



Nylon line
Adult 140 cm
Pediatric 90 cm

Gelatin capsule

4 hrs to overnight

Distal half scrapped off onto a slide by gloved fingers

Mix with saline
Observe under microscope for TROPHOZOITE

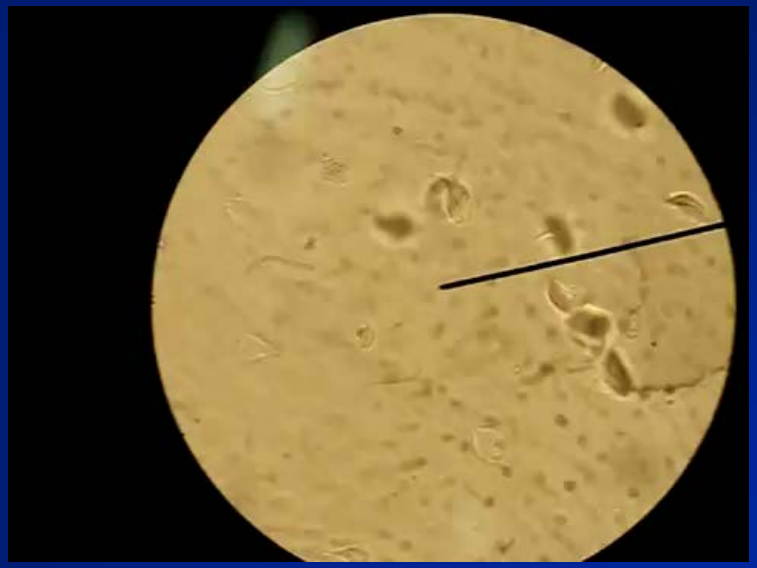

Stool Examination

collect at least 3 stool specimens on alternative days

Finding cyst in faeces

the cysts are passed irregularly.
Often large numbers may be present for a few days, followed by fewer numbers for a week or more

Finding motile flagellates in acute diarrhoeic faeces

Faecal specimens have an offensive smell, usually pale and fatty, often contains mucus

Examination of diarrhoeic faeces for Giardiasis

Specimens: offensive smell, pale and fatty, often contains mucus

Concentration: Formol ether concentration technique
Formol detergent sedimentation technique
Zinc sulphate flotation technique

Stain: cyst - eosin or iodine
flagellate - Field's rapid stain

Stage: mostly cysts and less commonly, motile flagellates

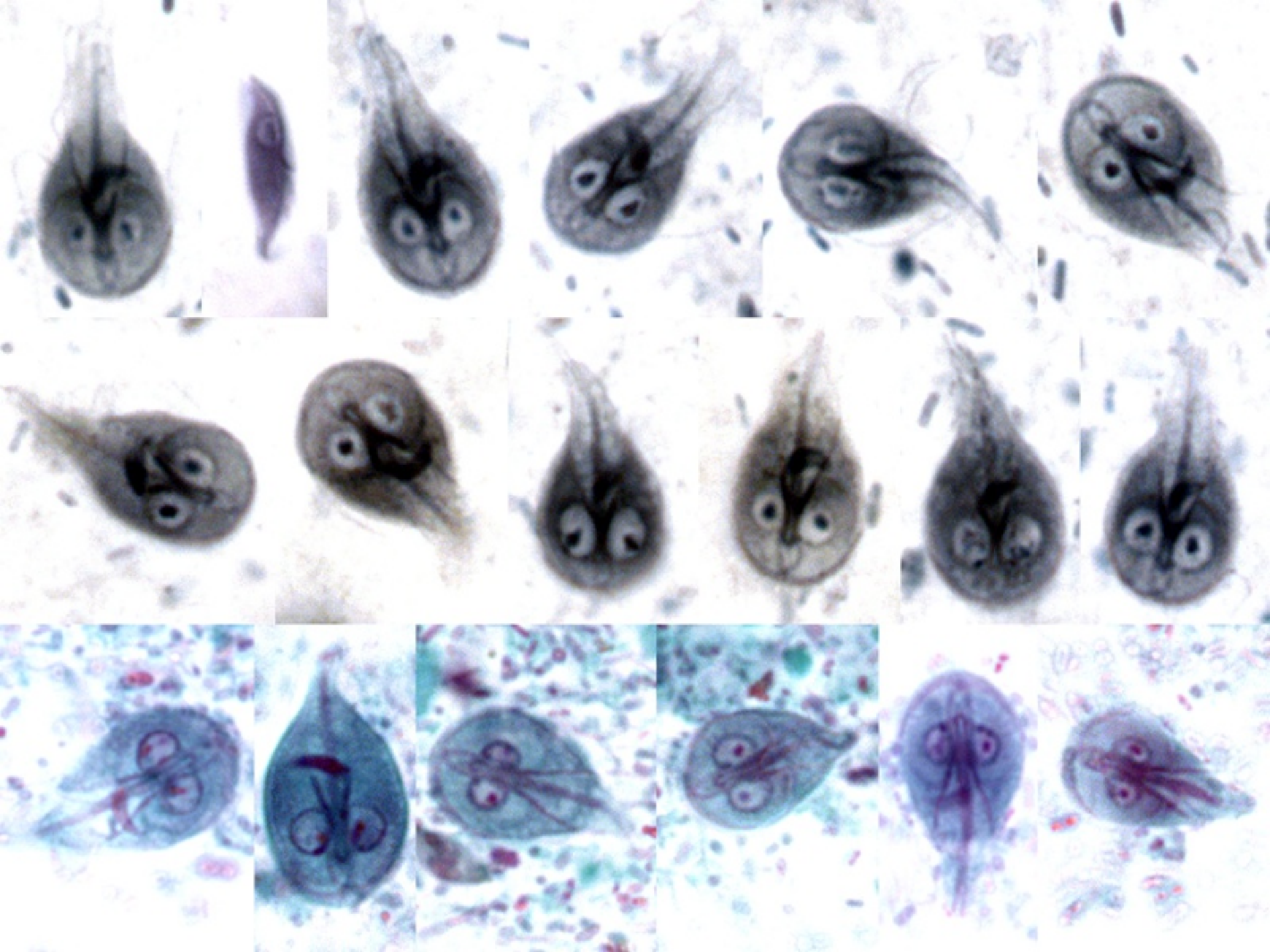

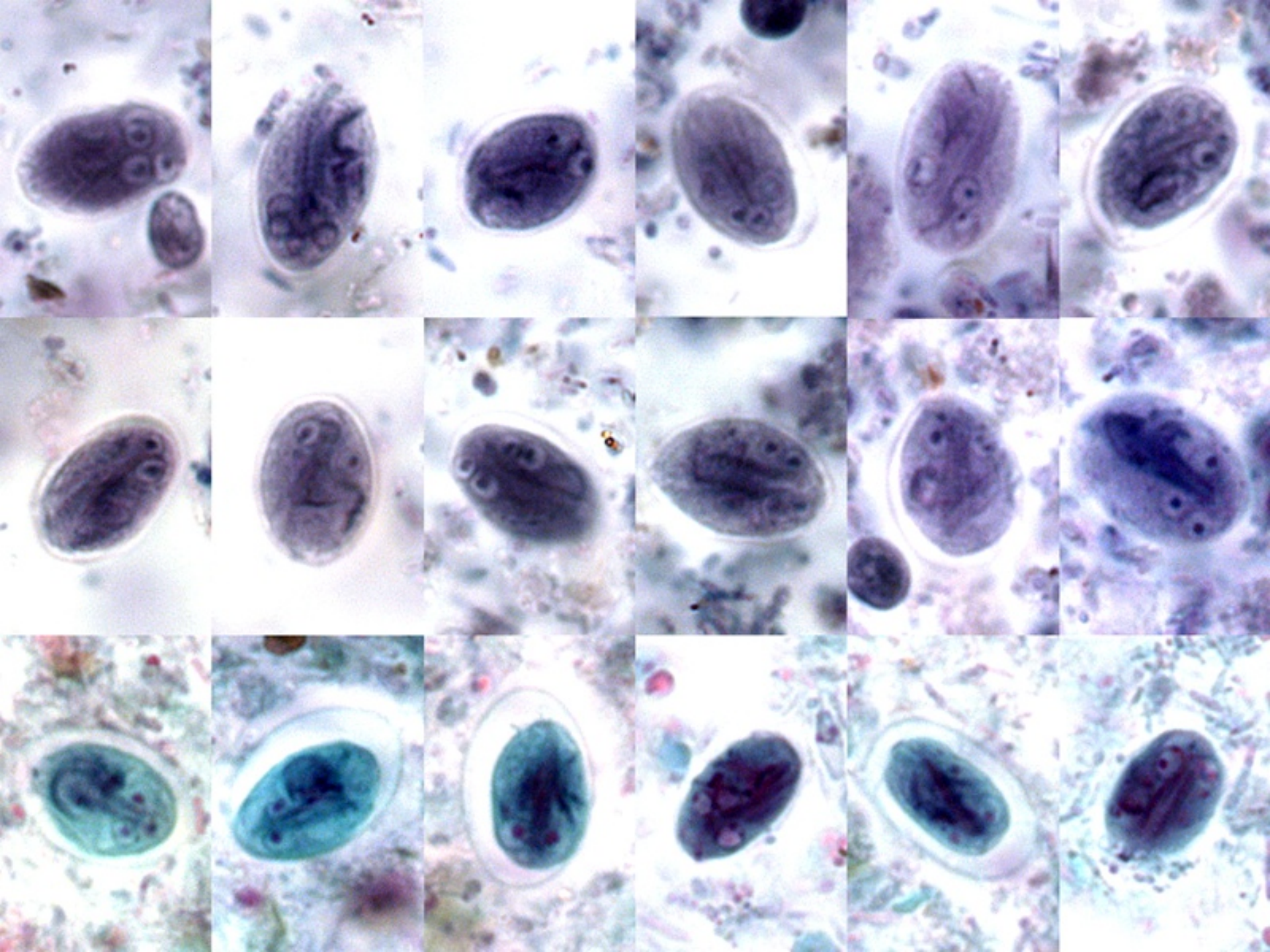

Treatment

- **Metronidazole (Flagyl)**
  400 mg (adult), 5 mg/kg (children) , tid,
  for 5~7 days or 2~2.5 g once daily for 3 days
- **Tinidazole**
  A single dose of 2 g for adults
  30 ~ 35 mg/kg for children
- **Mepacrine**
  100 mg, tid for 5~7 days
- **Furazolidone**
  10 mg/kg daily for 5 days (max. 600 mg/day)
- **Albendazole**
  400 mg daily for 5 days
- **Quinacrine HCl (Atabrine)**
  0.1g t.i.d for 5 days

Metronidazole (Flagyl) a disulfiram drug

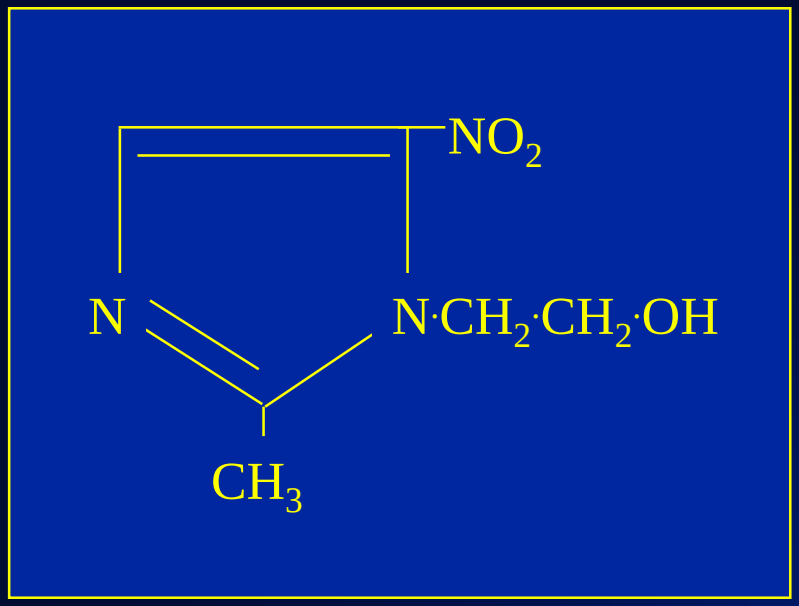

Side effects
nausea
dryness of the mouth
perception of metallic taste
consequent anorexia
intolerance to alcohol
tetratogenic in animals

Dosage:
2.0 g per day for 7 days; 250 mg, tid for 5 days
<2 yrs - 125 mg/day; 2~4 yrs: 250 mg/day;
4~8 yrs: 375 mg/day; 8~2 yrs: 500 mg/day

Potential carcinogenic and mutagenic in rodents
Not to be used by women
during the first three months of pregnancy and
newborns during the first six weeks of life

GIARDIASIS PREVENTION

- Avoid drinking water from sources associated with outbreaks
- Water filtration
- Chlorination is not effective
- In day cares; wash hands and proper disposing of diapers
- Hikers and backpackers should be warned to boil or filter water
- Swimming pools are specially vulnerable

B0202017 高博庠
Giardia lamblia
CAVS
23
B0202032 陳秋君
醫學三
Giardia
lamblia
Vogue
5月封面
B0202044 王凱瑜
B0202037 医学三 陳柏仲
Giarda lamblia
醫學三A B0202048 張晉瑜
Giardia lamblia
trophozoite
B02.2007
陳柏鈞
Giadia lamblia
B0202033 黃世炘
Giardia lamblia.

一夜情沒戴套 男染2性病

滴蟲傳染力超強 攝護腺癌機率高

【蔡明樺／台北報導】沒戴套就嘿咻，小心一「砲」雙響。一名二十九歲男子日前到夜店尋歡，與陌生女子發生一夜情，他沒戴保險套就提槍上陣，事後小便出現灼熱、疼痛感，就醫竟發現同時感染披衣菌、滴蟲兩種性病。醫師表示，六成性病患者同時染兩種以上的性病，嘿咻應戴保險套才不會樂極生悲。

書田診所昨開記者會，指蒐集去年門診收治的一百五十八位染淋病、梅毒、疱疹等性病患者，進行滴蟲快速篩檢，發現有十五人同時感染滴蟲，比率近一成，且危險性行為的滴蟲傳染率極高，男傳女幾乎百發百中，女傳男機率也達六成。

收治病例的書田診所泌尿科醫師周固表示，男子因一夜情太興奮，沒戴套就嘿咻，結果一砲雙響，同時被傳染披衣菌、滴蟲。他說，性病傳染特性為多重感染，每五位患者中，約三人同時染有兩種以上性病。

感染孕婦恐早產

周固說，滴蟲是一種梨型原蟲（Protozoan），在顯微鏡下才看得清楚，七成的男性滴蟲帶原者不會有症狀，少數男性會出現小便時有灼熱或疼痛感；而女性遭感染後，陰道會有黃白色分泌物、散發異味，尤其懷孕女性的陰道酸鹼值很適合滴蟲繁殖，若延誤治療，恐致早產或傳染給新生兒。

15分鐘就可篩檢

林口長庚醫院泌尿科醫師陳煜說，少數染滴蟲的男性患者，會出現射精帶血等症狀，且有研究顯示，其罹患攝護腺癌或不孕的機率也較高；過去滴蟲篩檢不易，現在有尿液快篩試劑後，只要十五分鐘就知道是否染病，自費價約一千兩百元。

應避免共用毛巾

周提醒，有研究報告指與他人共用毛巾與馬桶座，可能會成為傳染滴蟲媒介，民眾應盡量避免，且嘿咻時男性戴保險套，也可預防感染滴蟲等性病。

■醫生說明滴蟲侵害生殖系統，會由尿道（手指處）入侵到內部其他器官。 胡瑞麒攝

防治滴蟲性病 注意事項

- 行房前，男性先戴保險套，避免直接傳染或感染
- 勿多重性伴侶、一夜情
- 行房後女性若陰道分泌物增多、男性小便時有灼熱或疼痛感，應與性伴侶一同就醫
- 懷孕女性若延誤治療，恐致早產、傳染給新生兒
- 有研究顯示，男性若感染滴蟲，罹患攝護腺癌機率較高

資料來源：周固醫師、陳煜醫師

TRICHOMONIASIS陰道鞭毛蟲症

a sexually transmitted infection (STI)
caused by the flagellate

Trichomonas vaginalis

陰道鞭毛蟲/陰道毛滴蟲

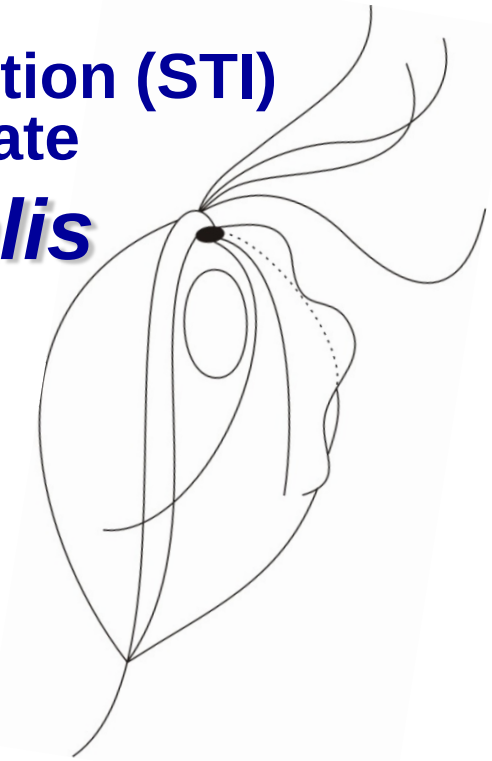

Worldwide distribution
with the highest prevalence in females of sexually active groups

Trichomoniasis: A Neglected Sexually Transmitted Disease

1836
Animalculi observed in purulent fluids and secretions of genital organs from men and women.(1836) *Comptes rendus hebdomadaires des séances de l'Académie des sciences.* V3:p385

Alfred François Donné
(1801–1878)

1920s

1924 High prevalence and cosmopolitan distribution of trichomoniasis in women recognized

1940s

1945 Reports of *Trich* as "dimly understood" cause of urethritis in men

1950s

1957 Trichomonas culture

1959 Metronidazole (MTZ) introduced for treatment

1960s

1962 First report of clinical resistance to MTZ

1970s

1975 Trichomoniasis considered one of the "minor venereal diseases"

1980 - 2000s

1990 Trichomonas recognized as a co-factor for HIV transmission

1999 Ned Hook declares *T. vaginalis* "no longer a minor sexually transmitted disease"

The Most Neglected STD

Trichomoniasis	**174 million**
Chlamydia	92 million
Gonorrhea	62 million
Syphilis	12 million
Global Total	240 million

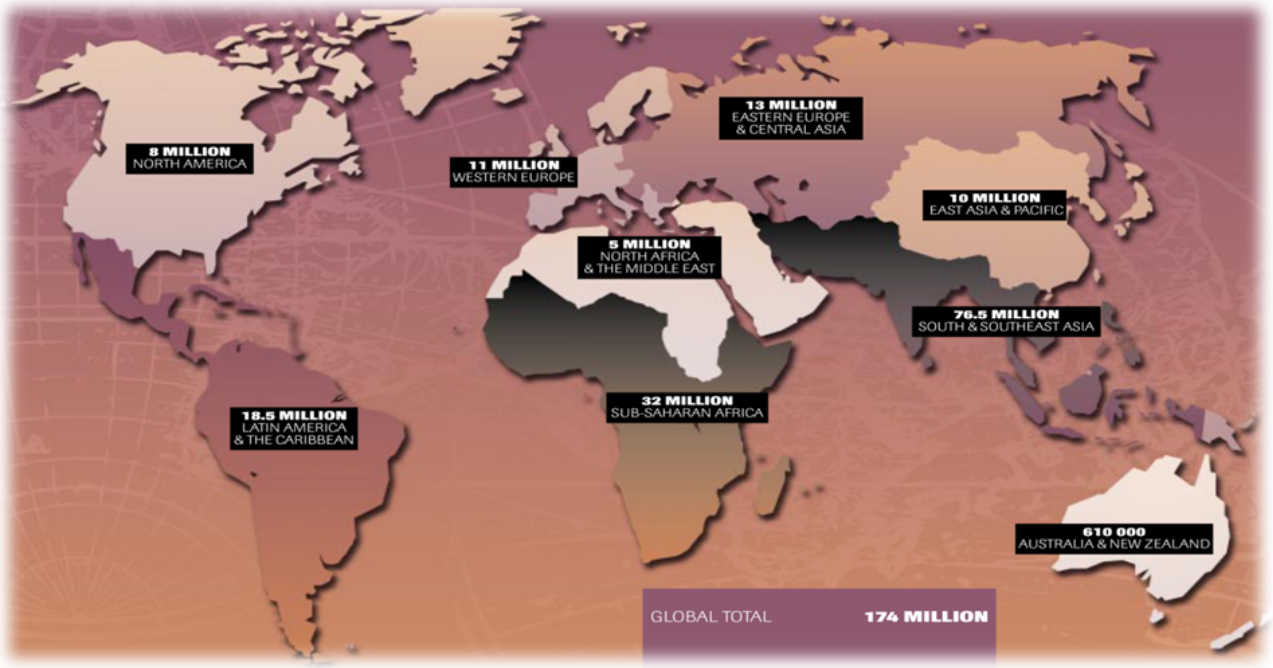

Approximately 5 million cases were reported annually in North America. Worldwide, over 170 million cases of Trichomoniasis are reported each year.

Morphology of *T. vaginalis* trophozoite

梨形
長約 7~23 um (平均 13 um), 寬約 5~15 um
前端有 4 根鞭毛
第 5 根鞭毛附著於活動體上, 形成波動膜
後端有一軸柱突出體外
可見一大型細胞核及副基體

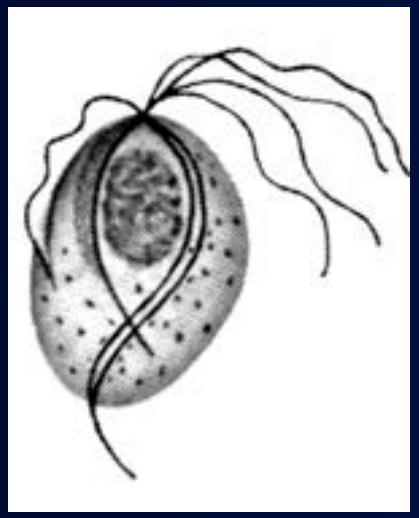

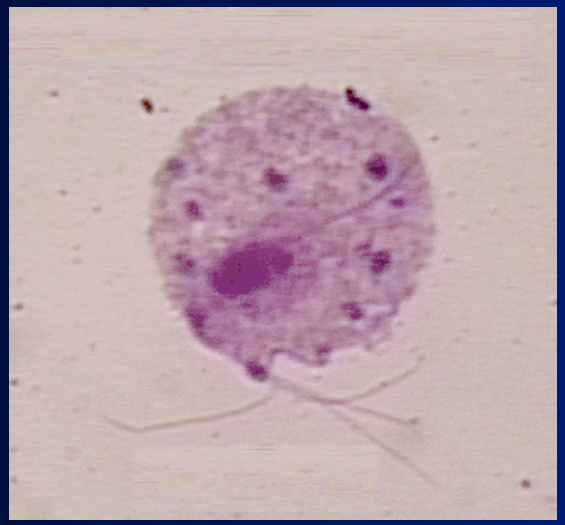

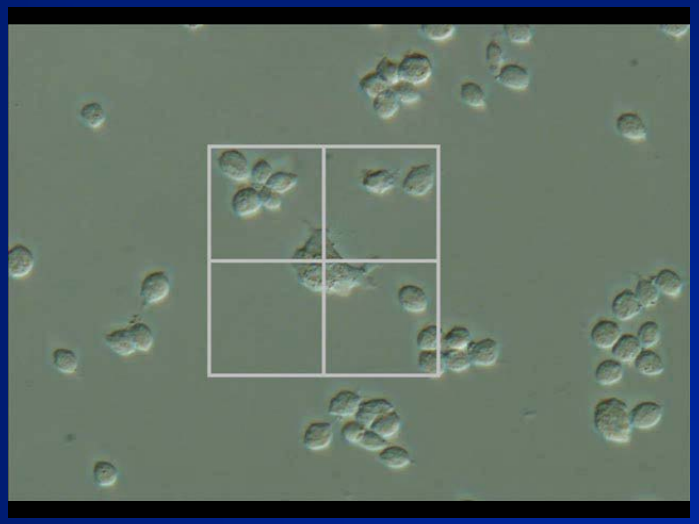

Transmission

Infective form: Trophozoite

- Person to person by sexual contact
- Contact with articles contaminated with vaginal discharges

T. vaginalis can survival up to five days at 0°C at optimum condition in pseudocyst (假囊體) form (moist, pH<4.9)

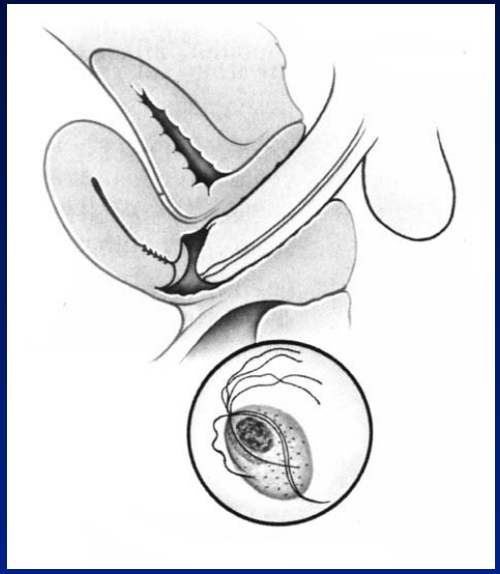

***T. vaginalis* live in the urogential tract 泌尿生殖道 of both women and men**

蘋果日報 I 20100208

女泡溫泉 下體發癢飄腥臭味

染陰道滴蟲症 長期發炎恐致不孕

2010年02月08日蘋果日報

泡溫泉時應慎選水質乾淨場所，以防感染陰道滴蟲症。圖中溫泉池並非個案浸泡處。資料照片

【沈能元/台北報導】天冷是泡溫泉的旺季。一名女子日前泡完溫泉後，隔兩天感覺下體分泌物多，且散發著魚腥味，就醫診治發現是感染陰道滴蟲症。醫師表示，滴蟲是種寄生蟲，可經由性行爲、浸泡不淨的池水，寄居於女性陰道，提醒女性在上述行爲後，出現下體有魚腥味情況，應盡速就醫，否則可能導致不孕。

注意衛生

收治病例的台北市立聯合醫院中醫門診中心中醫師羅珮琳表示，這名二十多歲女子就醫時自述日前泡過溫泉，之後就下體發癢、分泌物多且臭臭的，經檢查是罹患陰道滴蟲症，隨即將其轉介至婦產科接受治療。

多經性行爲傳染

台北醫學大學附設醫院婦產科主任張景文說，陰道滴蟲症是由滴蟲所引發的疾病，多經由性行爲傳染，但該蟲離開人體於水中仍能短暫存活，若上述女子沒性行爲，且在泡完溫泉幾天內發病，有可能是浸泡帶有滴蟲的溫泉水才感染。

署立雙和醫院婦產科主治醫師楊振銘說，罹患陰道滴蟲症的女性，除易有下體分泌物多、搔癢、散發魚腥般異味外，長期不治療，更可能使子宮頸反覆發炎導致不孕。

宜避免泡大眾池

楊振銘說，治療陰道滴蟲症以抗生素爲主，性伴侶也要一併接受治療。在預防上除單一性伴侶外，泡溫泉時應慎選池水潔淨場所，少泡大眾池；若證實感染陰道滴蟲症，治療期間勿再泡溫泉，除避免傳染他人，溫泉水的酸鹼值也易改變陰道偏酸的環境，讓滴蟲繁殖更快，增加治療困難度。

楊振銘也建議女性使用坐式公廁時，應先鋪上坐墊紙，避免直接接觸。書田診所泌尿科主任洪峻澤說，男性感染滴蟲，多無明顯症狀，但嚴重者仍可能出現頻尿、排尿疼痛或困難等不適。

陰道滴蟲症防治 注意事項

- 泡溫泉時，應選擇較乾淨池水
- 泡溫泉後應全身洗淨，並將陰部擦乾
- 使用坐式公廁時，應先鋪上馬桶坐墊紙
- 陰道分泌物增加，且有類似魚腥般異味時，有可能是罹患陰道滴蟲症，應速就醫

公共浴池泡澡 恐得陰道滴蟲

作者： 蔡惠玲 | 台灣醒報 – 2013年5月16日 下午4:20

-字 +字

【台灣醒報記者蔡惠玲台北報導】民眾在公共浴池泡澡，小心得性病陰道滴蟲。書田診所泌尿科主任林儒廷及新店耕莘醫院泌尿科姜秉均醫師都表示，陰道滴蟲除經由性行爲感染外，還會透過公共浴池、被汙染的毛巾、游泳池、澡堂及溫泉感染。很多人誤認爲陰道滴蟲女性才有，其實男性也會被感染。

「五成女性患者、七成男性患者，感染陰道滴蟲沒有明顯症狀。」姜秉均表示，女性可透過陰道分泌物，較易檢驗出感染，但男性不易透過尿道檢驗。女性感染陰道滴蟲後，可能引發骨盆腔發炎、慢性陰道發炎。

林儒廷表示，門診中有一位男性患者，因尿道癢就醫，後來醫生進行檢測滴蟲反應爲陽性，醫生詳細詢問後，了解可能使用宿舍公用澡盆泡澡，經由澡盆而感染陰道滴蟲。

他說，陰道滴蟲喜愛生存於潮濕的環境，滴蟲即使離開人體後，在潮濕的環境下如濕毛巾，仍可存活一段時間，活動力雖會下降，但一旦遇到水，活力又增強。文獻上曾出現，女童因爲與父親使用同一條毛巾而間接傳染。

林儒廷指出，陰道滴蟲常見症狀有：尿道癢、分泌物增加、異味、排尿疼痛、灼熱等。有部分男性會發生攝護腺炎、副睪丸炎、龜頭包皮炎等，由於症狀不明顯，因此常被忽略。

林儒廷提醒民眾，男性感染陰道滴蟲時傳染女伴的機會，大於女性感染陰道滴蟲傳染給男伴。治療時，性伴侶應同時接受治療，以免持續交互感染，導致無法痊癒。

Atyptical infection: Pulmonary trichomoniasis

In newborns

T. vaginalis acquired from mother during delivery

In adults

T. vaginalis acquired by "oral-vaginal" conatct

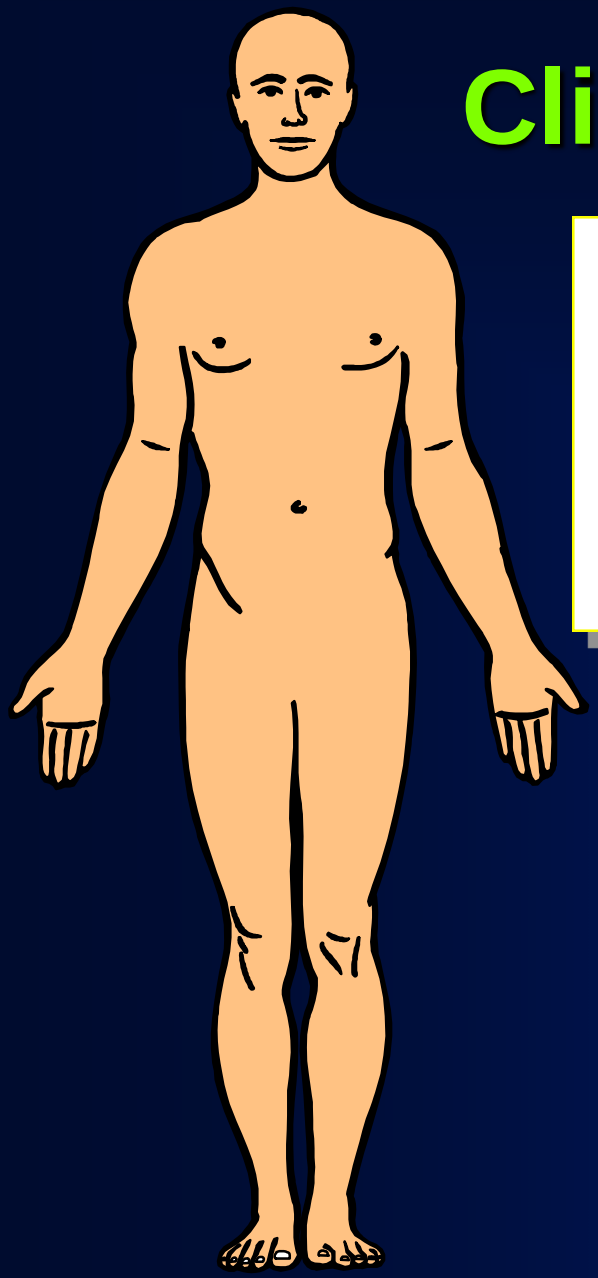

Clinical Symptoms - Males

Trophozoites live in the urethra 尿道 and prostate 前列腺

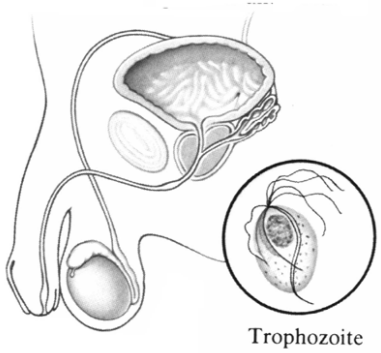

Usually asymptomatic - Carrier

Occasionally cause urethritis (尿道炎) or prostatitis (前列腺炎)

Urethral discharge is non-purulent

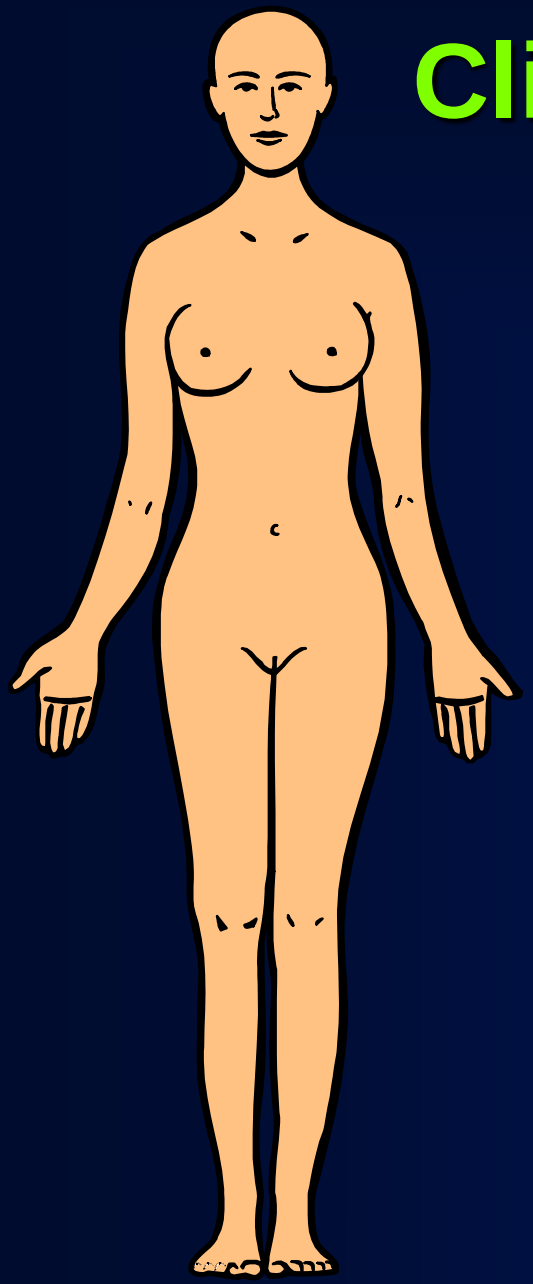

Clinical Symptoms - Females

Trophozoites live in the vagina cuase **Trichomonad vaginitis**

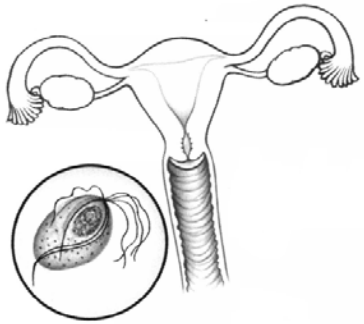

About 20% are asymptomatic
Onset usually after menstruation
Severe vaginal itching or burning
About 40% cause acute inflammation of vulva (陰部) and cervix (子宮頸)
Produce yellow-greeen purulent discharge.
Somtimes accompanied by urinary frequency

Pathological Changes

about 2/3 of the infected women shows

Exo-cervix epithelium

increased vascularity
edema
imflammation

Endocervical mucosa

basal hyperactivity
squamous metaplasia

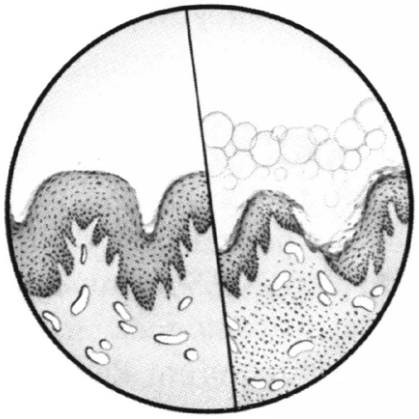

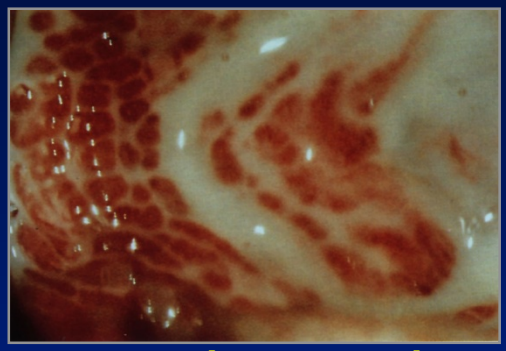

Strawberry cervix

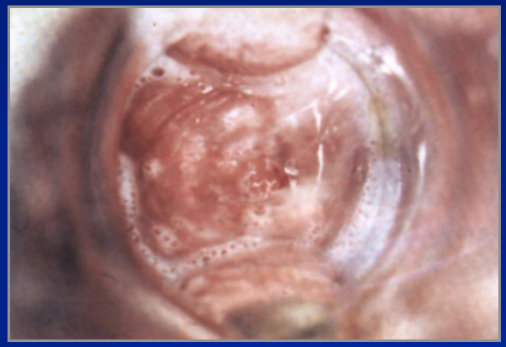

Vaginal erythema and discharge

Cytoaherence of *T. vaginalis* to vaginal epithelial cells (VEC)

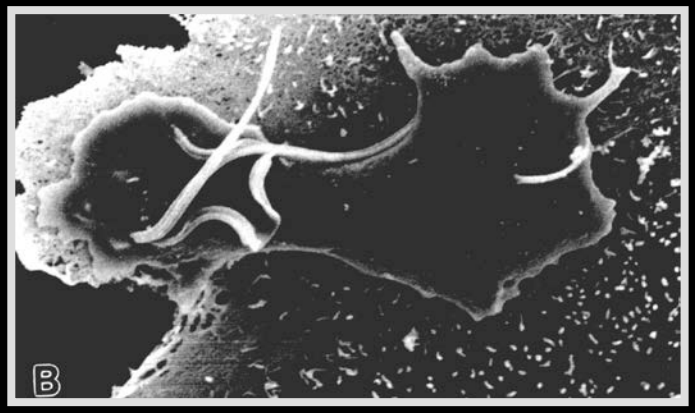

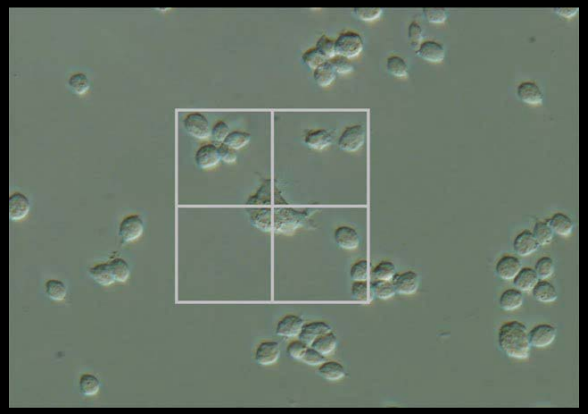

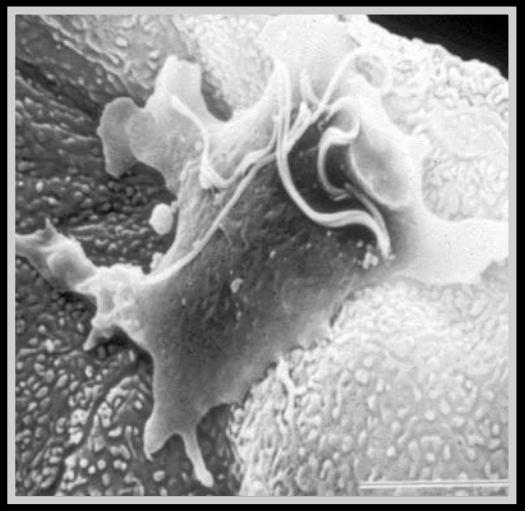

Trichomoniasis is associated with preterm delivery, low birth weight and increased infant mortality.

Infection also pre-disposes individuals to HIV/AIDS and cervical cancer.

Individuals infected with *T. vaginalis* have a significantly increased incidence of HIV transmission *(Cohen, 2000; Upcroft and Upcroft, 2001)* .

Diagnosis of Trichomoniasis

- Clinical presentation (臨床症狀)
- Finding *trophozoites* in wet mounts of vaginal discharges (陰道分泌物) or urethral discharges (尿液, 精液或前列腺液)
- *In-vitro* culture (體外培養) of vaginal or urethral discharges in TYI medium

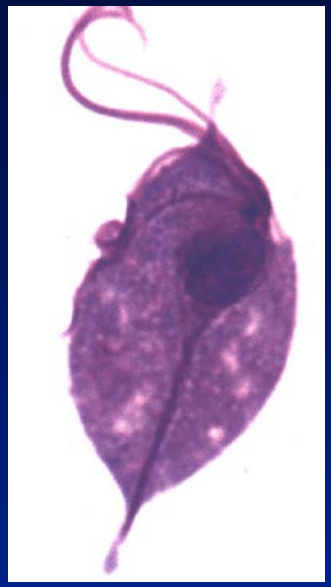

BIOMED

INPOUCH™ TV (Trichomonas Vaginalis)

InPouch™ TV is a highly specific and sensitive device allowing for simultaneous growth and observation of *Trichomonas vaginalis*, the parasite responsible for the STI Trichomoniasis. The InPouch™ TV is known as "The Gold Standard" diagnostic for this STI. The proprietary medium of the InPouch™ TV is selective for the transport and growth of *T. vaginalis* and increases specificity by inhibiting the growth of yeasts, mold, bacteria, and other commensal micro flora. No slide preparation is required to view *T. vaginalis* in the InPouch™

DETECTS	T. vaginalis
STORAGE	Room Temperature (18-25 °C)
INCUBATION	37°C



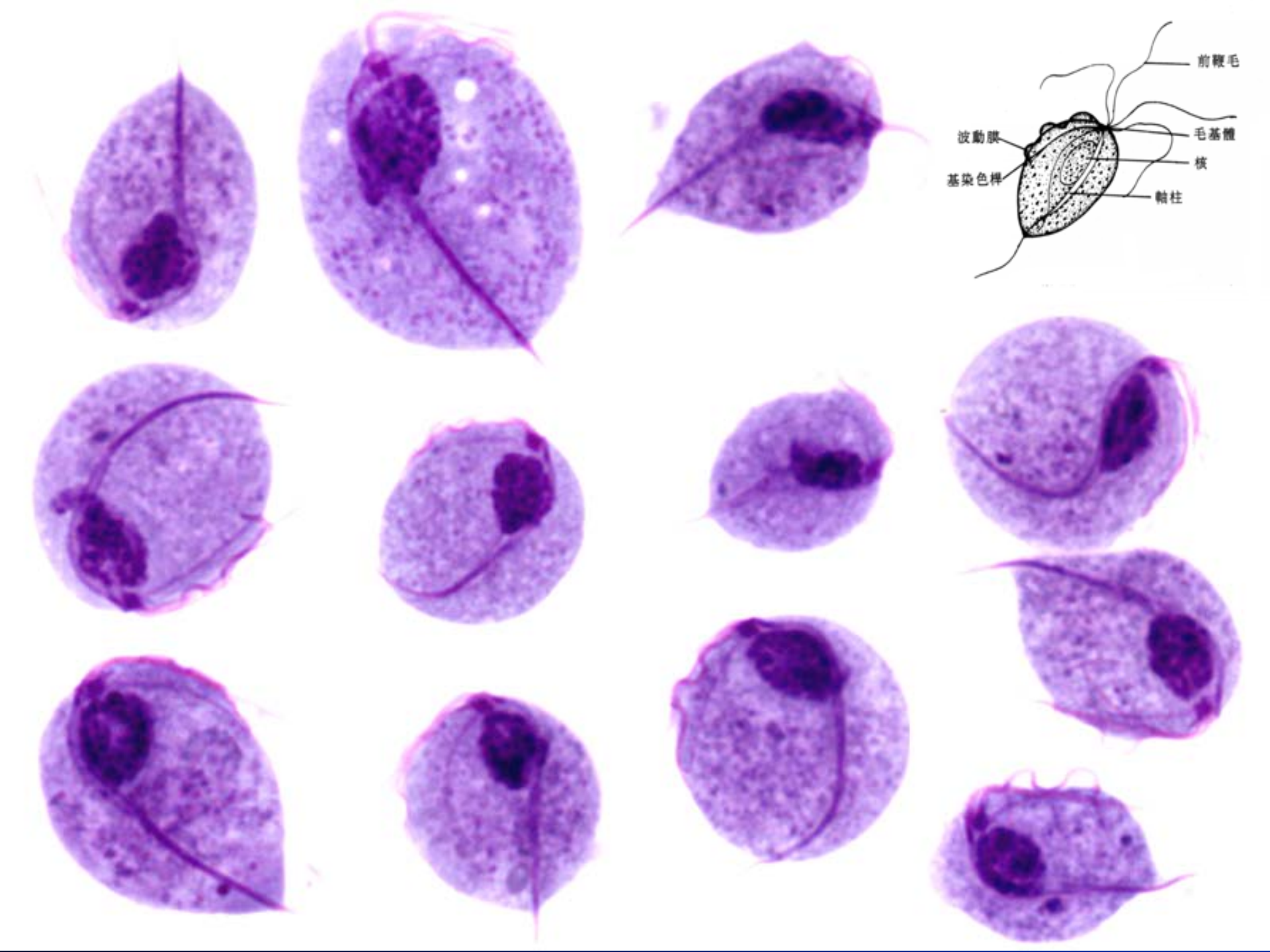
前鞭毛
波動膜
毛基體
核
基染色桿
軸柱

人體寄生鞭毛蟲之形態比較

	陰道鞭毛蟲 *T. vaginalis*	腸道鞭毛蟲 *P. hominis*	口腔鞭毛蟲 *T. tenax*
寄生部位	陰道, 尿道	腸道	口腔
波動膜	相當於蟲體1/3~2/3	與蟲體等長	相當於蟲體2/3~3/4
前鞭毛	4	3~5	4
後鞭毛	1,不游離	1,不游離	1,不游離
核	核膜內染色質粒較細 核仁甚小或無	核膜內無染色質粒 核仁大而明顯	核膜內有較多染色質粒 故染色較深,無核仁

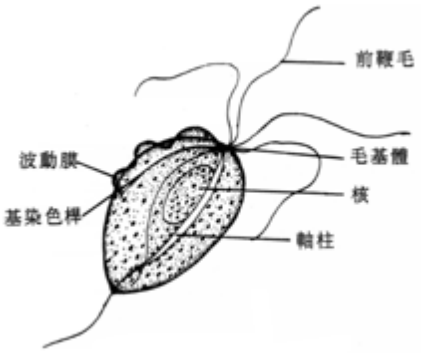

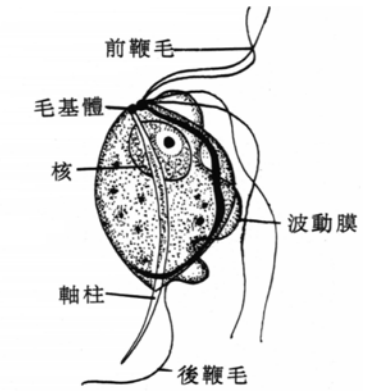

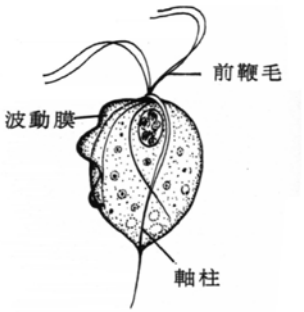

The Life Cycle of Trichomonas vaginalis

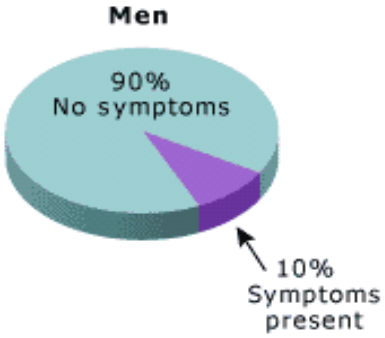

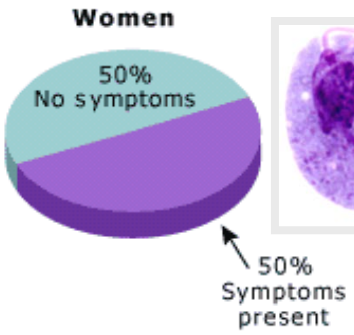

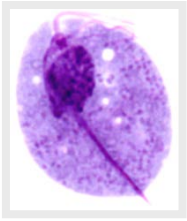

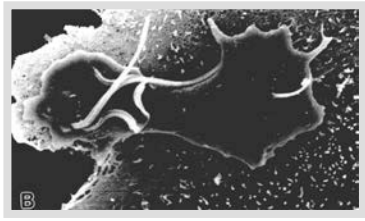

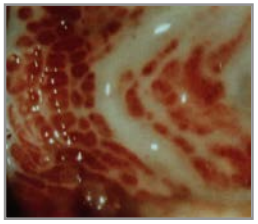

Strawberry cervix

Vaginal erythema

Metronidazole (Flagyl) a disulfiram drug

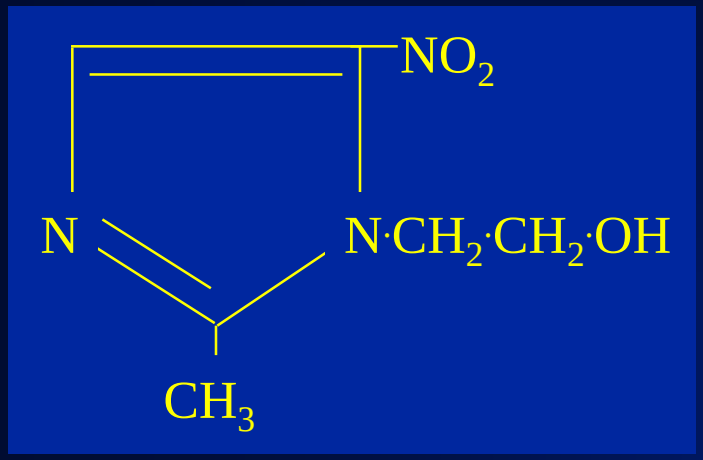

Side effects
nausea
dryness of the mouth
perception of metallic taste
consequent anorexia
intolerance to alcohol
tetratogenic in animals

Potential carcinogenic and mutagenic in rodents

Not to be used by women during the first three months of pregnancy and newborns during the first six weeks of life

https://tw.appledaily.com/headline/daily/20180527/38025980/

OL染滴蟲 私密處搔癢 芳療可防羞羞病

茶樹精油棉條塞下體 2周後改善

12719 出版時間：2018/05/27

【江慧珺／台北報導】芳香療法夯，不僅舒緩身心，還有輔助治療效果。一名33歲OL私密處反覆感染滴蟲，搔癢難耐，與另一半嘿咻也大受影響，之後在醫師指導下尋求精油芳療，用衛生棉條沾取稀釋過的茶樹精油，睡前塞在陰道，2周後搔癢與感染情況大幅改善。

擁有芳療師證照的台安醫院家庭醫學科主任羅佳琳指出，鼻腔的嗅毛會接收空氣中的芳香分子，將刺激轉成電波，直接刺激大腦內的杏仁核與海馬迴，這兩處正是掌管情緒與記憶的部位，進而達到放鬆、改善情緒問題的功效。

Petrus Tang · 在Chang Gung University擔任教授

請勿誤導大眾。若茶樹精油可以預防或治療陰道鞭毛蟲(滴蟲)感染，請提供臨床研究資料。陰道鞭毛蟲感染非常容易治療。病人應直接求診以免延誤加重病情。
並請貴報日後有寄生蟲感染相關報導時，應先向專家學者求証。
台灣寄生蟲學會 理事長 鄧致剛 教授

讚 · 回覆 · 5 · 11小時

Chilomastix mesnili

唇形鞭毛蟲

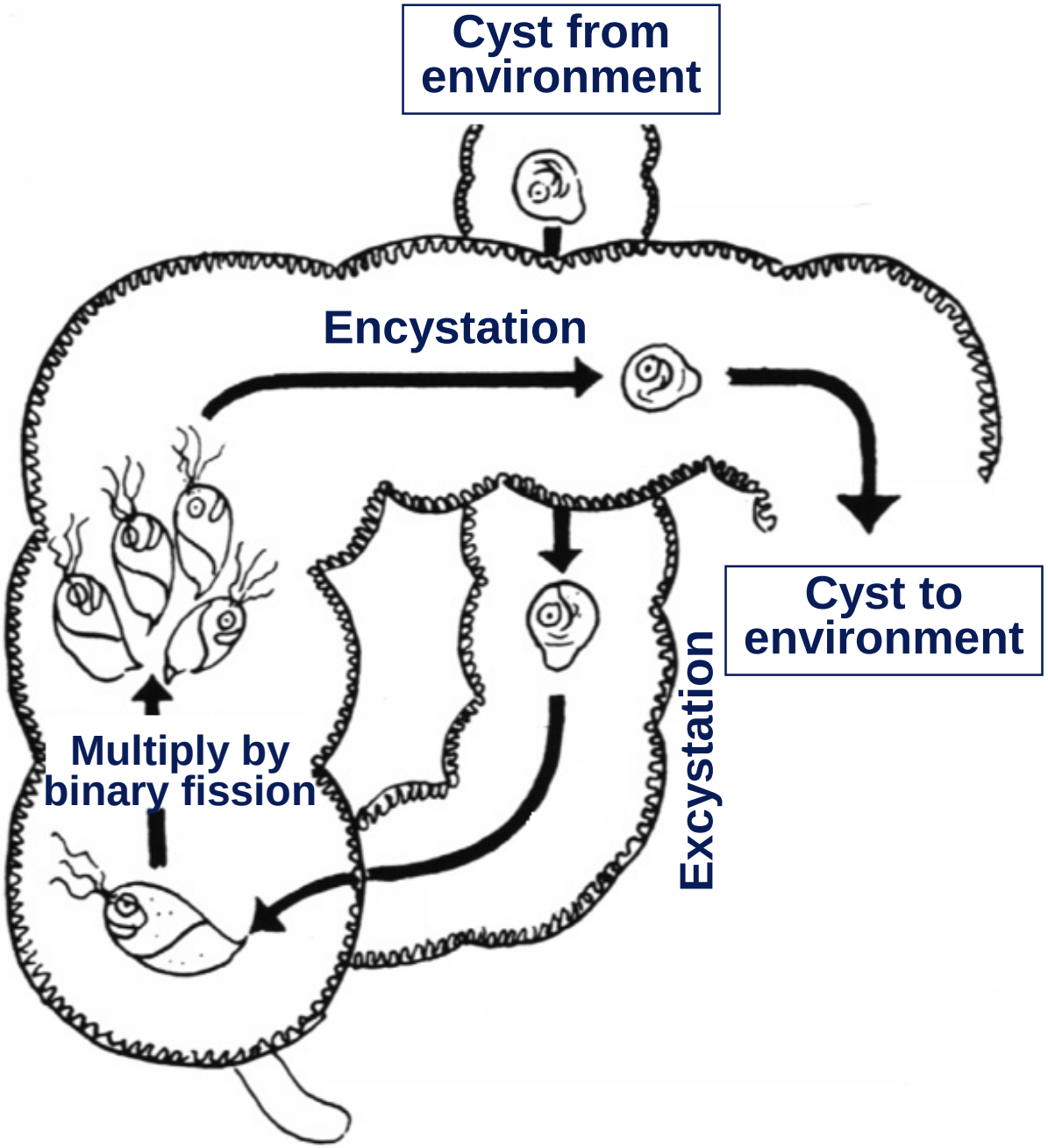
Cyst from environment
Encystation
Cyst to environment
Excystation
Multiply by binary fission

【活動體】
大小：6～20 X 3～10 um
形狀：梨形，前端鈍圓，未端尖銳。
構造：
（1）胞口位於體前端，左右兩緣較厚，
　　呈口唇狀，向後延伸約佔蟲體一半。
（2）核：圓形或卵圓形，位於蟲體前端
（3）鞭毛：前排3根 鞭毛（1長2短），游離於蟲體煎端。
　　後排1根較短的鞭毛，向後伸人胞口
　　另2個各發出纖絲一條
（4）嫘旋溝：從體前端的背面開始，轉入體後端的
　　腹面，為體表的螟旋狀凹陷。

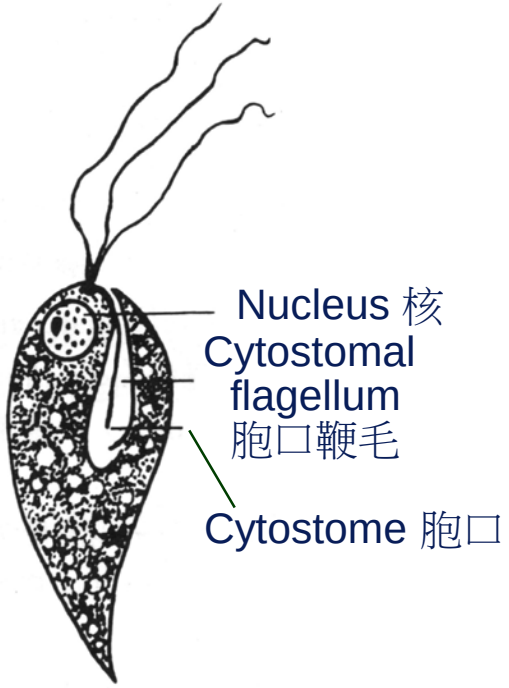

【囊體】
大小：7～10 X 4～6 um。
形狀：檸檬形或卵圓形。
構造
（1）囊壁薄，但前端厚
（2）核：1~2 個，
（3）有胞口，內有鞭毛及纖絲等。

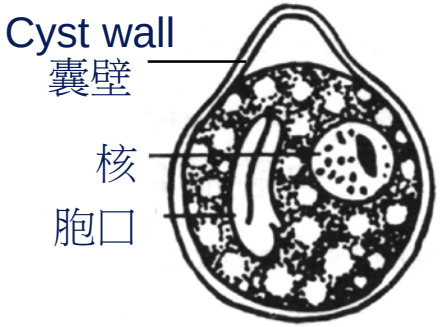

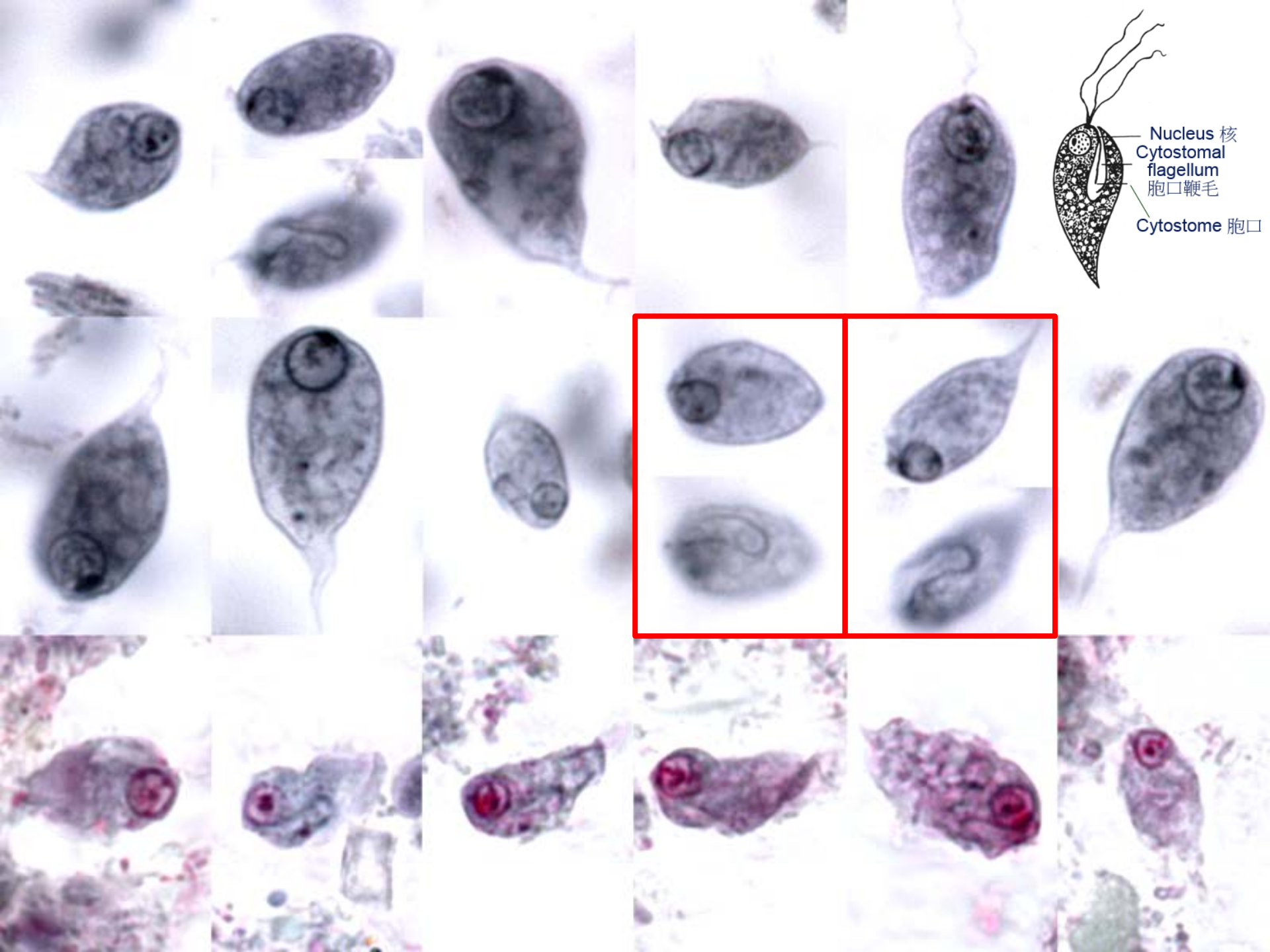
Nucleus 核
Cytostomal flagellum
胞口鞭毛
Cytostome 胞口

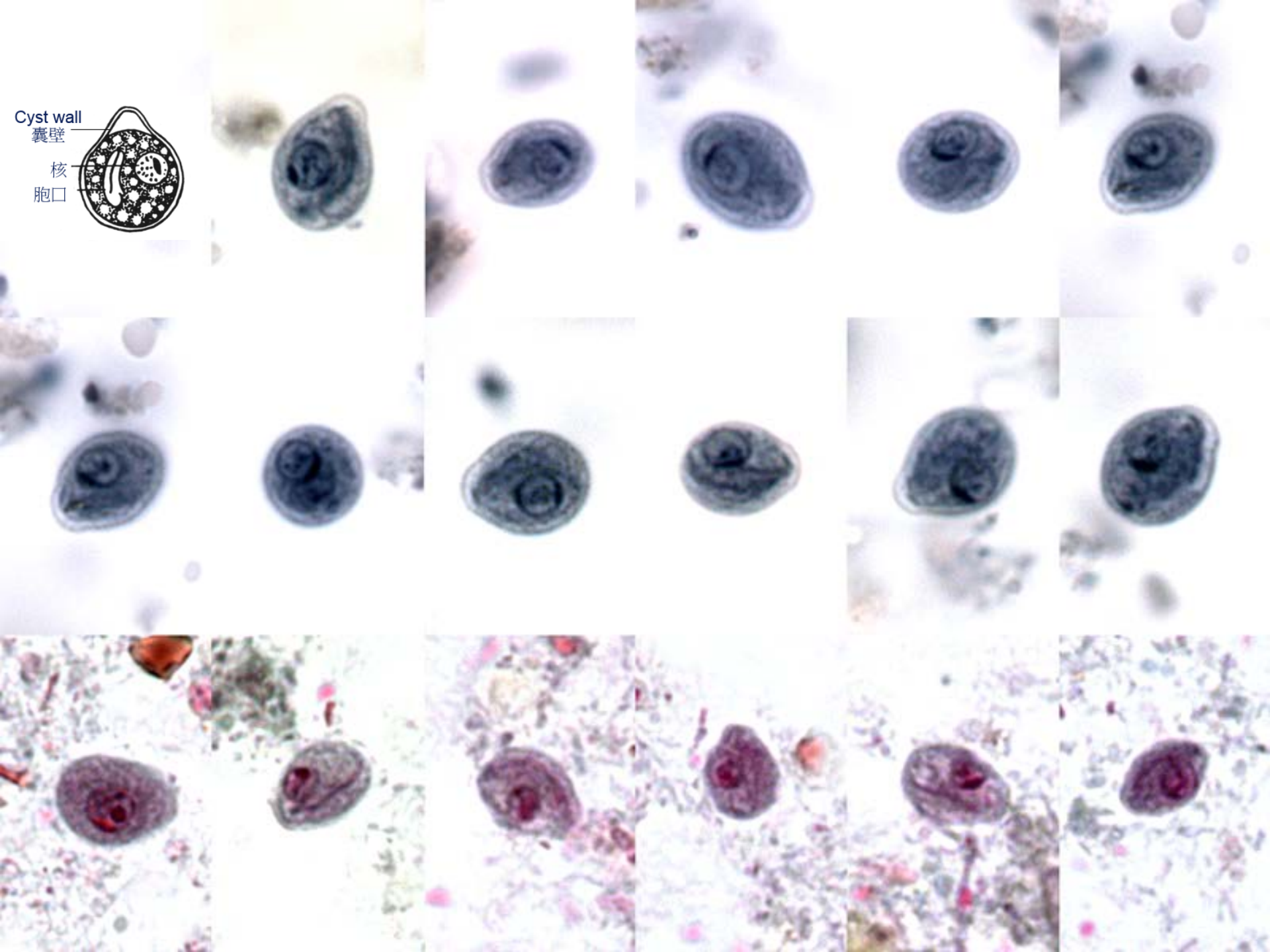
Cyst wall
囊壁
核
胞口